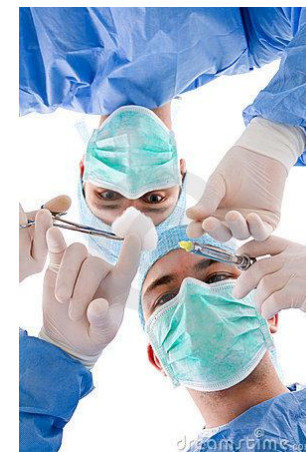



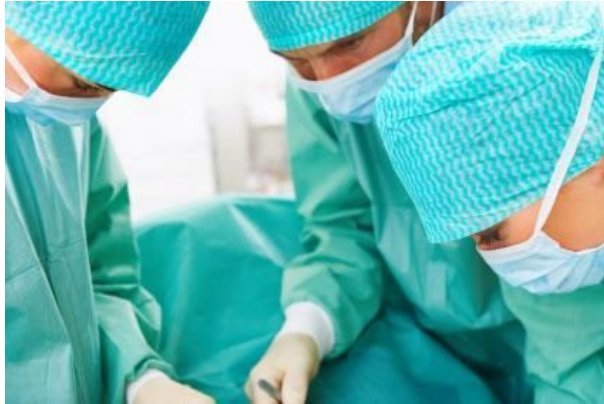CIRURGIA NA URGÊNCIA

Clara Rocha; João Dores

Orientadores: Dr. António Godinho, Dr. José Calado

Director serviço Cirurgia C: Dr. Nuno Pinheiro

Equipa cirurgia:
5 elementos



Gabinete Cirurgia

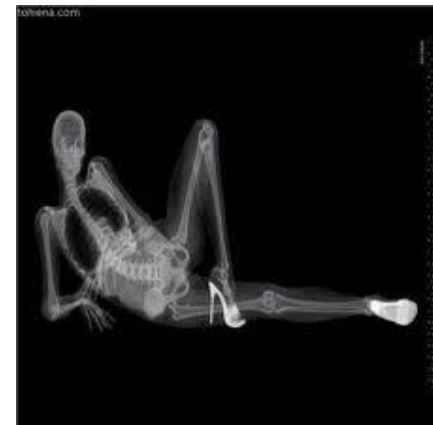- Trauma torácico
- Dor abdominal
- Neoplasias
- Pós-operatórios
- ...

Pequena Cirurgia

- Traumatismos c/ feridas
- Feridas pediátricas
- Patologia ano-rectal
- Queimaduras
- ...

Exames imagiológicos que se pedem mais no SU....

- Rx tórax
- Rx abdómen simples em pé
- TC-CE
- Ecografia abdominal
- TC abdominal

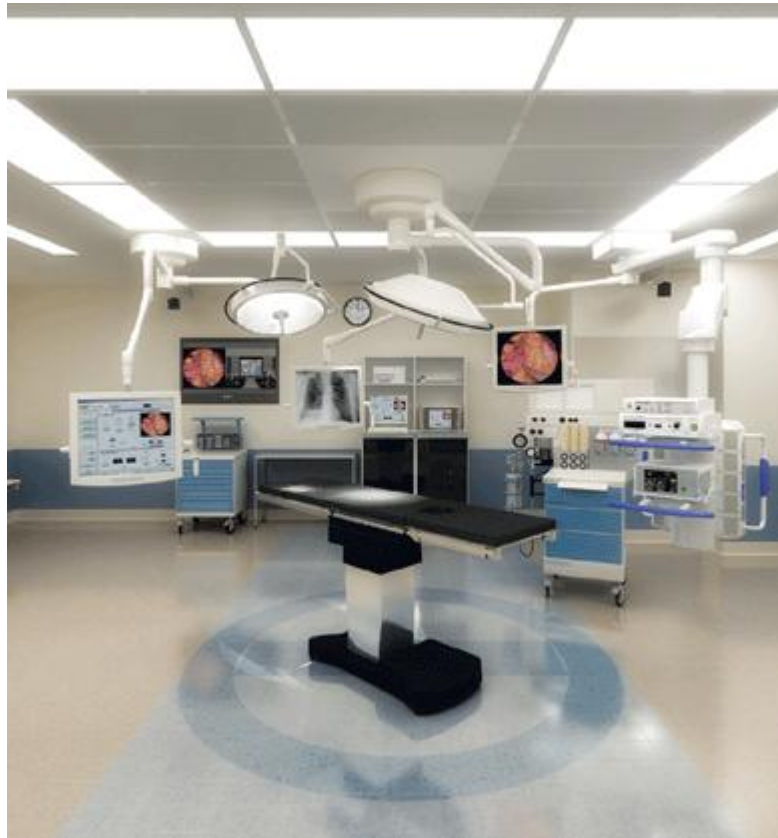
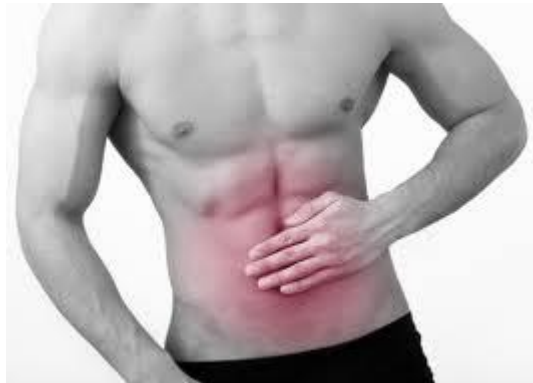
Dor Abdominal....

Abdómen cirúrgico:

Como se diagnostica....

Quando operar...



Inflammatory

Secondary bacterial peritonitis: localized, generalized

Primary bacterial peritonitis: generalized

Tertiary peritonitis: generalized, very poor prognosis

Traumatic

Injury to solid organs: acute intra-abdominal bleeding

Peritonitis secondary to intestinal injury

Obstructive

Acute intestinal obstruction (small bowel)

Chronic intestinal obstruction (colonic)

Vascular

Mesenteric infarction

Strangulated external/internal herniae

Volvulus (small or large intestine)



Causas comuns de dor abdominal que levam ao SU:

Dor abdominal não específica	35
Apendicite Aguda	30
Colecistite aguda e cólica biliar	10
Doença péptica	5
Oclusão delgado	5
Alterações ginecológicas	5
Pancreatite aguda	2
Cólica renal	2
Doença maligna	2
Diverticulite aguda	2
Dispepsia	1
Outras	5



História clínica

Dor?

Quando?Onde?Como?

Abrupta?Gradual?

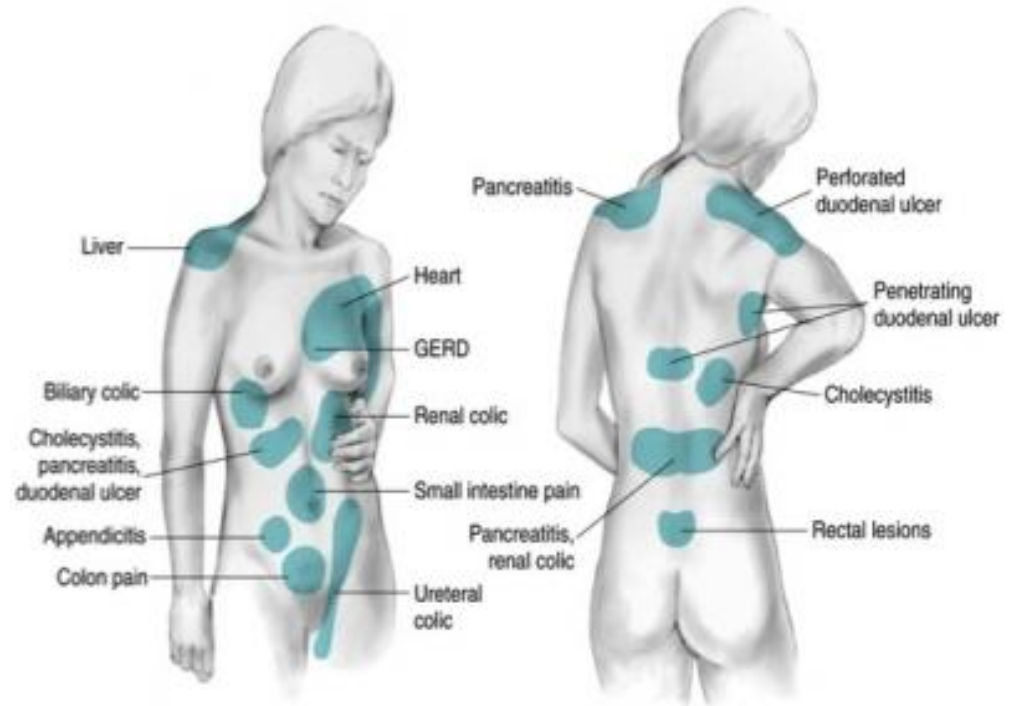
Características?

Irradiação?

Repetição?Inicial?

Vómitos?

Relações com a dor?



Náuseas? Anorexia?

Movimentos intestinais?

História pessoal médica e cirúrgica?

Viagens?

Última refeição?

Revisão sistémica?



Exame Objectivo

Aspecto e posição do doente

Sinais vitais

Aspecto do abdómen

Distensão

Hérnias

Cicatrizes

Palpação

Depressível

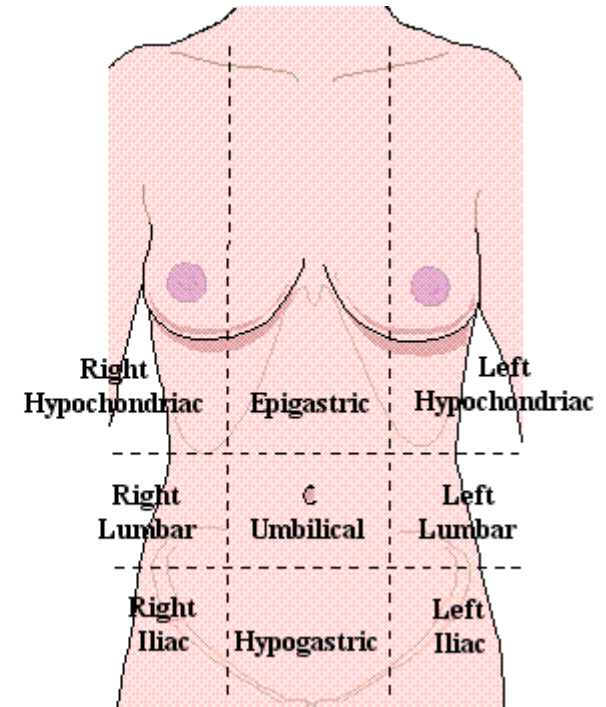
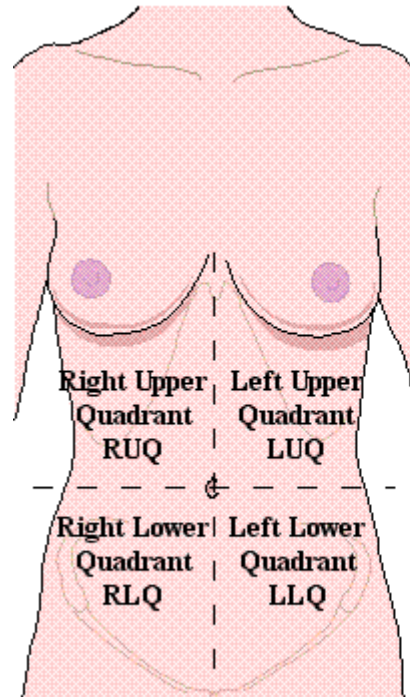
Ventre em tábua

Massas

Auscultação abdómen

Toque rectal

Observação outros sistemas



Sinai's dor abdominal:

SIGN	DESCRIPTION	DIAGNOSIS/CONDITION
Aaron sign	Pain or pressure in epigastrium or anterior chest with persistent firm pressure applied to McBurney's point	Acute appendicitis
Bassler sign	Sharp pain created by compressing appendix between abdominal wall and iliacus	Chronic appendicitis
Blumberg's sign	Transient abdominal wall rebound tenderness	Peritoneal inflammation
Carnett's sign	Loss of abdominal tenderness when abdominal wall muscles are contracted	Intra-abdominal source of abdominal pain
Chandelier sign	Extreme lower abdominal and pelvic pain with movement of cervix	Pelvic inflammatory disease
Charcot's sign	Intermittent right upper abdominal pain, jaundice, and fever	Choledocholithiasis
Claybrook sign	Accentuation of breath and cardiac sounds through abdominal wall	Ruptured abdominal viscus
Courvoisier's sign	Palpable gallbladder in presence of painless jaundice	Periampullary tumor
Cruveilhier sign	Varicose veins at umbilicus (caput medusae)	Portal hypertension
Cullen's sign	Periumbilical bruising	Hemoperitoneum
Danforth sign	Shoulder pain on inspiration	Hemoperitoneum
Fothergill's sign	Abdominal wall mass that does not cross midline and remains palpable when rectus contracted	Rectus muscle hematomas
Grey Turner's sign	Local areas of discoloration around umbilicus and flanks	Acute hemorrhagic pancreatitis
Iliopsoas sign	Elevation and extension of leg against resistance creates pain	Appendicitis with retrocecal abscess
Kehr's sign	Left shoulder pain when supine and pressure placed on left upper abdomen	Hemoperitoneum (especially from splenic origin)
Mannkopf's sign	Increased pulse when painful abdomen palpated	Absent if malingering
Murphy's sign	Pain caused by inspiration while applying pressure to right upper abdomen	Acute cholecystitis
Obturator sign	Flexion and external rotation of right thigh while supine creates hypogastric pain	Pelvic abscess or inflammatory mass in pelvis
Ransohoff sign	Yellow discoloration of umbilical region	Ruptured common bile duct
Rovsing's sign	Pain at McBurney's point when compressing the left lower abdomen	Acute appendicitis
Ten Horn sign	Pain caused by gentle traction of right testicle	Acute appendicitis



Meios Complementares de diagnóstico

Análises - Hemograma, Iono, FR, FH, PCR, Urina II

Rx – Abd simples em pé/ decúbito dorsal/ decúbito lateral esquerdo

Ecografia – Eleição: Alterações biliares/ TGU/ liquido livre

Desvantagem: Operador dependente/ Baixa sensibilidade para vísceras ocas/ Gás e obesidade

TC – Eleição: patologia retroperitoneal/ traumatismo vísceras maciças/PA/ complicações cirúrgicas/aneurismas

Desvantagens: Custo elevado



Caso Clínico I



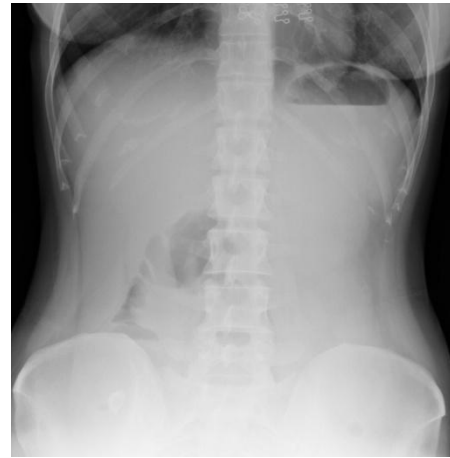- , 20 A
 - Motivo SU: Dor na FID com 12h de evolução
 - Refere náuseas
 - AP-desconhece
-
- EO- Abd- mole, depressível, doloroso FID com sinal Blomberg +.



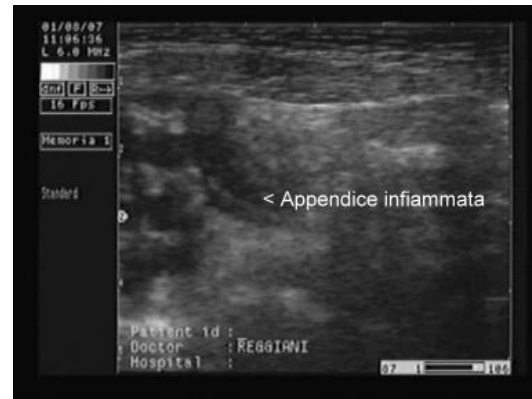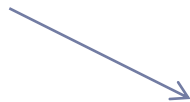MCDT:

Análises: Leucocitose (15.000); PCR 5

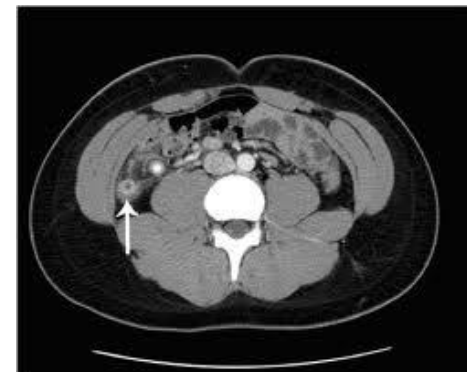Rx abd em pé



Ecografia abdominal



TC abdomén

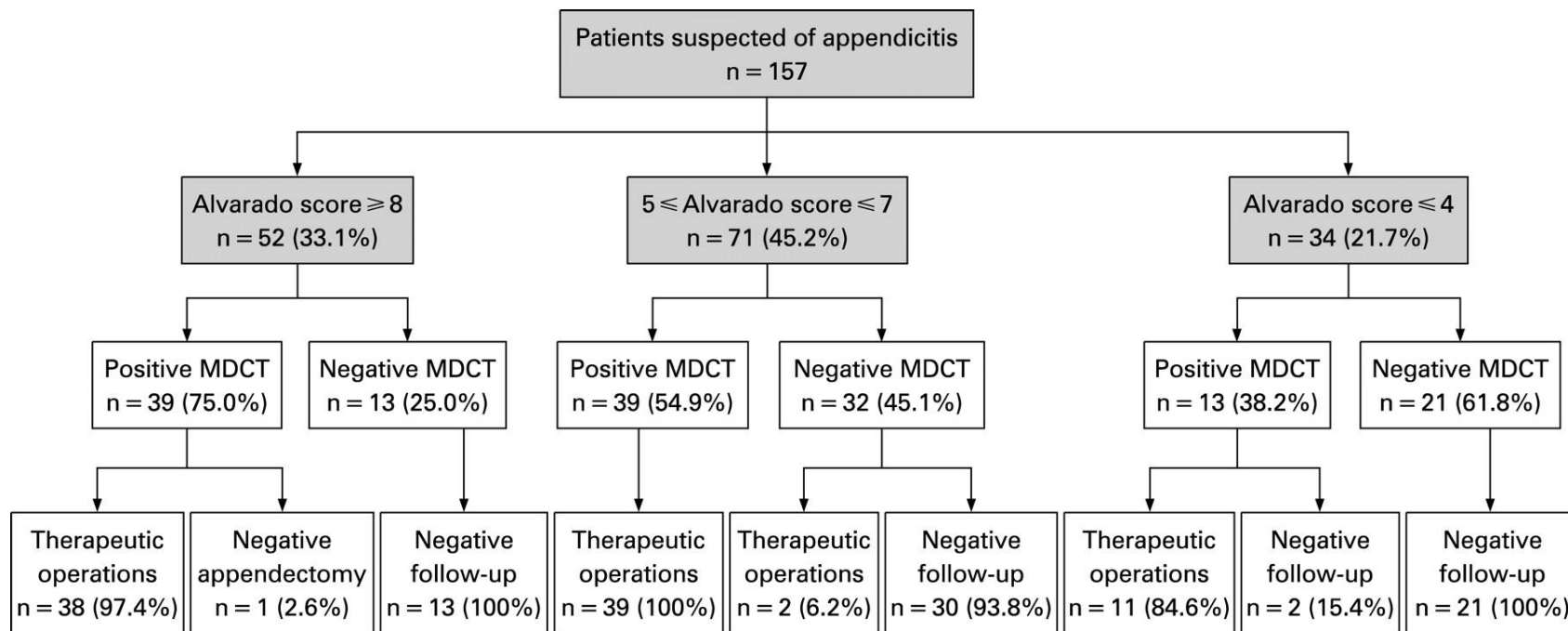


Apendicite e MCDT....

Alvarado score for appendicitis

Symptoms	Score
Migratory right iliac fossa pain	1
Nausea / Vomiting	1
Anorexia	1
Signs	
Tenderness in right iliac fossa	2
Rebound tenderness in right iliac fossa	1
Elevated temperature	1
Laboratory findings	
Leucocytosis	2
Shift to the left of neutrophils	1
Total	10

5-6 → Possible
7-8 → Probable
> 9 → Very probable



Diagnóstico diferencial Apendicite Aguda:

Adenite Mesentérica

Divertículo Meckel

DII

Carcinoma cego

Alterações Ginecológicas:

Rotura folículo ovárico (Mittelschmerz)

Salpingite aguda

Rotura gravidez ectópica

Torção quisto ovário

Genito-urinário:

Pielonefrite

Cólica urinária

ITU

Torsão testículo direito



Caso Clínico II



- , 18 A
- Motivo SU/Reanimação: Ferida por arma branca no abdómen
- Muito queixoso; hálito etílico
- AP- desconhece

- Abd- mole, depressível, indolor palpação profunda. Porta de entrada de arma branca 2 cm no flanco esquerdo com integridade da aponevrose após inspecção.



MCDT:

Análises: Hb-14, sem alt coagulação

Rx abd em pé – sem alterações

Opções:

Vigilância/ repetir Rx

Ecografia/TC:

-Evisceração

-Quadro peritoneal

-Instabilidade hemodinâmica

-Dúvidas



Contents of the 'trauma' compartments of the abdomen:

Intrathoracic

Diaphragm

Liver

Spleen

Stomach

True abdominal

Small and large intestine

Pregnant uterus

Distended urinary bladder

Pelvic

Sigmoid colon

Rectum

Small-bowel loops

Bladder

Urethra

Ovaries and uterus

Retroperitoneal

Kidney and ureters

Duodenum

Pancreas

Aorta

Inferior vena cava



Caso Clínico III

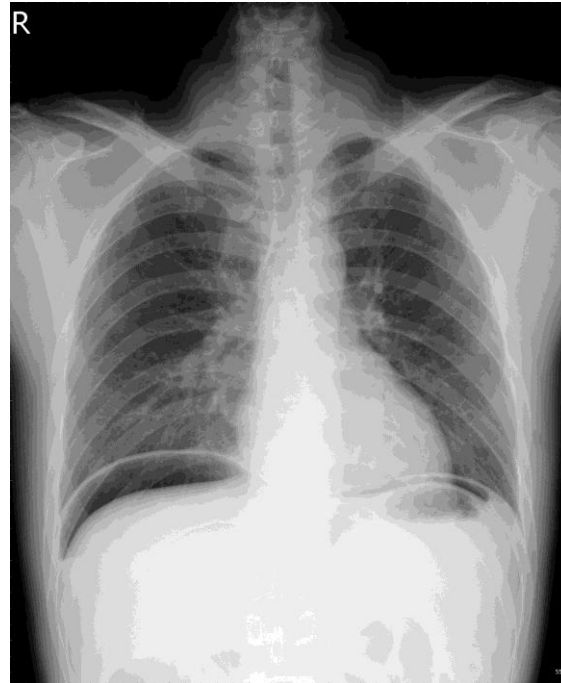
- , 40 A
 - Motivo SU: Dor epigástrica com 4h de evolução
 - Refere alívio da dor em posição semi-flectida
 - AP- Hábitos tabágicos moderados
-
- Abd- Ventre em tábua



MCDT:

Análises: Leucocitose (19.000); PCR 16

Rx tórax com cúpulas →



Pneumoperitoneu



Bloco operatório



Causas pneumoperitoneu no RX:

Perfuração víscera

Infecção com produção gás

Fistula pleuroperitoneal

Iatrogénica: Laparoscopia; laparotomia

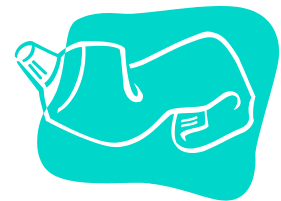
Gás introduzido pela vagina: post-parto

Interposição de intestino entre fígado e diafragma



Caso Clínico IV

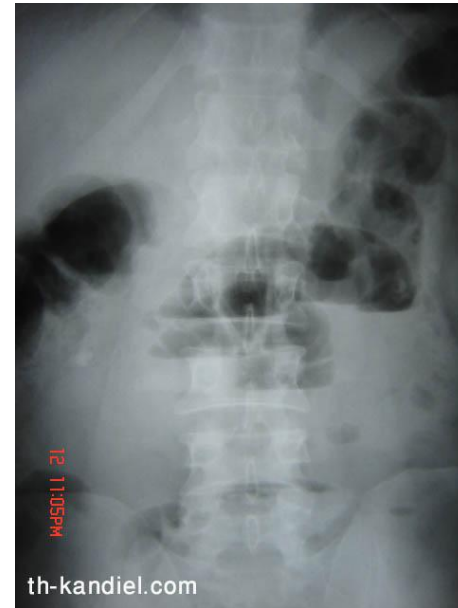- , 80 A
 - Motivo SU: Paragem de emissão de gases e fezes há 8 dias
 - Refere perda de peso ligeiro
 - AP- Status pós AVC, HTA medicada, patologia cardíaca
- Abd- distendido, timpanizado, doloroso palpação profunda em todo o abdómen.
Toque rectal- ampola vazia



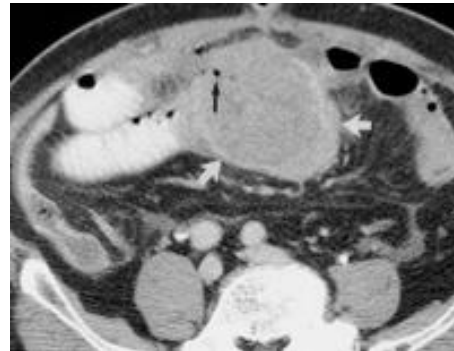

MCDT:

Análises: Leucocitose (14.000); PCR 15;

Rx abd em pé



TC abdómen



Causes of mechanical intestinal obstruction:

Extramural

Adhesions, bands

Herniae: external and internal

Compression by tumours (nodal tumour deposits)

Intramural

Inflammatory disease: Crohn's disease

Tumours: carcinomas, lymphomas, etc.

Strictures

Intraluminal

Faecal impaction

Swallowed foreign bodies

Bezoars

Gallstone



Caso Clínico V

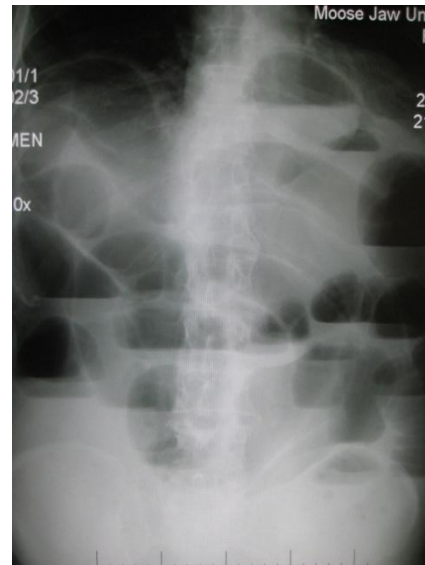
- , 70 A
 - Motivo SU: Distensão abdominal, dor nos quadrantes superiores
 - Refere náuseas e vômitos
 - AP- Apendicectomia; dislipidémia
-
- Abd- Cicatriz mediana, distendido, doloroso palpação profunda em todos os quadrantes. Toque rectal- fezes na ampola.



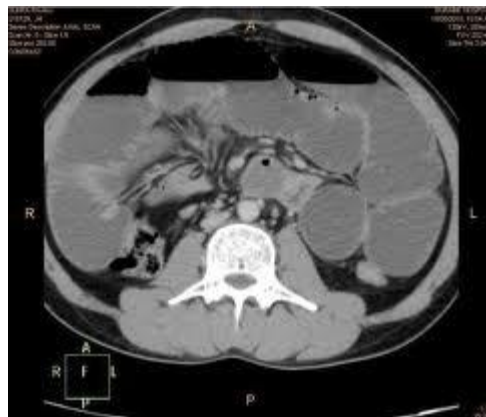
MCDT:

Análises: Leucocitose (20.000); PCR 6;

Rx abd em pé



TC abdómen



Guidelines for Operative and Nonoperative Therapy

Situations necessitating emergent operation

- Incarcerated, strangulated hernias
- Peritonitis
- Pneumatosis cystoides intestinalis
- Pneumoperitoneum
- Suspected or proven intestinal strangulation
- Closed-loop obstruction
- Nonsigmoid colonic volvulus
- Sigmoid volvulus associated with toxicity or peritoneal signs
- Complete bowel obstruction

Situations necessitating urgent operation

- Progressive bowel obstruction at any time after nonoperative measures are started
- Failure to improve with conservative therapy within 24/48 hr
- Early postoperative technical complications

Situations in which delayed operation is usually safe

- Immediate postoperative obstruction
 - Sigmoid volvulus successfully decompressed by sigmoidoscopy
 - Acute exacerbation of Crohn disease, diverticulitis, or radiation enteritis
 - Chronic, recurrent partial obstruction
 - Paraduodenal hernia
 - Gastric outlet obstruction
 - Postoperative adhesions
 - Resolved partial colonic obstruction
-



Caso Clínico VI

- , 40 A
 - Motivo SU: Dor no hipocôndrio direito
 - Refere náuseas e vômitos
 - AP- Dislipidemia
-
- Abd- mole, depressível, doloroso hipocôndrio direito com defesa. Murphy vesicular +.

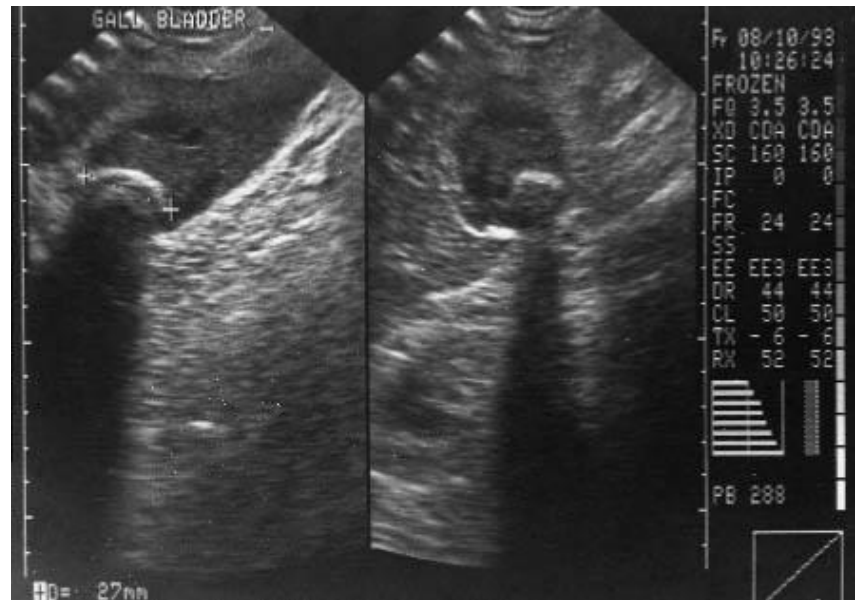


MCDT:

Análises: Leucocitose (14.000); Alt. FH. BilT 2 Amilase 1200; PCR 6;

Rx abd em pé

Ecografia abdominal



Risk factors for gallstone prevalence and symptomatic gallstone disease:

Increased prevalence

Female sex*

Obesity*

Age*

Genetic and ethnic factors*

Diet depleted in fibre and high in animal fats*

Diabetes mellitus*

Ileal disease and resection

Haemolytic states

Infections of the biliary tract

Parasitic infestations

Cirrhosis

Cystic fibrosis

Precipitation of symptomatic disease

Pregnancy

Clofibrate

Thiazide diuretics

?Oral contraception

* Increased prevalence of cholesterol stones,
Increased prevalence of pigment stones.



Spectrum of symptomatic gallstone disease:

Chronic cholecystitis

Acute biliary colic/acute cholecystitis

Jaundice due to large bile duct obstruction

Cholangitis/septicaemia

Acute gallstone pancreatitis

Biliary fistulous disease

Gallstone ileus



Indications for emergency surgical intervention in patients with acute cholecystitis:

Progression of the disease despite conservative treatment

Failure to improve within 24 h especially in patients > 60 years old and Diabetics

Presence of an inflammatory mass in the right hypochondrium

Detection of gas in the gallbladder/biliary tract

Established generalized peritonitis

Development of intestinal obstruction

