

CASE REPORT

Hepatic abscess induced by foreign body: Case report and literature review

Sofia A Santos, Sara CF Alberto, Elsa Cruz, Eduardo Pires, Tomás Figueira, Élia Coimbra, José Estevez, Mário Oliveira, Luís Novais, João R Deus

Sofia A Santos, Sara CF Alberto, Elsa Cruz, Eduardo Pires, João R Deus, Department of Gastroenterology, Fernando Fonseca Hospital, IC19, Amadora 2720-276, Portugal
Tomás Figueira, Élia Coimbra, Department of Radiology, Fernando Fonseca Hospital, IC19, Amadora 2720-276, Portugal
José Estevez, Department of Surgery, Fernando Fonseca Hospital, IC19, Amadora 2720-276, Portugal
Mário Oliveira, Department of Pathology, Fernando Fonseca Hospital, IC19, Amadora 2720-276, Portugal
Luís Novais, Center for the Study of Esophageal Diseases, Carnaxide, Portugal

Correspondence to: Dr. Sofia A Santos, Department of Gastroenterology, Fernando Fonseca Hospital, Estrada Serra da Mira, N22, 3^o DTO 2700-786, Amadora,

Portugal. sofiasantos_md@sapo.pt

Telephone: +351-965-628190

Received: 2006-06-03

Accepted: 2007-02-07

Abstract

Hepatic abscess due to perforation of the gastrointestinal tract caused by ingested foreign bodies is uncommon. Pre-operative diagnosis is difficult as patients are often unaware of the foreign body ingestion and symptoms and imaging are usually non-specific. The authors report a case of 62-year-old woman who was admitted with fever and abdominal pain. Further investigation revealed hepatic abscess, without resolution despite antibiotic therapy. A liver abscess resulting from perforation and intra-hepatic migration of a bone coming from the pilorum was diagnosed by surgery. The literature concerning foreign body-induced perforation of the gastrointestinal tract complicated by liver abscess is reviewed.

© 2007 The WJG Press. All rights reserved.

Key words: Liver abscess; Foreign body; Gastrointestinal perforation

Santos SA, Alberto SCF, Cruz E, Pires E, Figueira T, Coimbra E, Estevez J, Oliveira M, Novais L, Deus JR. Hepatic abscess induced by foreign body: Case report and literature review. *World J Gastroenterol* 2007; 13(9): 1466-1470

<http://www.wjgnet.com/1007-9327/13/1466.asp>

INTRODUCTION

Perforation of the gastrointestinal tract caused by ingested foreign bodies is uncommon and formation of posterior hepatic abscess is even more rare^[1-3]. In the majority of cases an early diagnosis is difficult to make by laparotomy due to the variability of clinical presentation and non specificity of complementary examinations. The authors report a rare case of gastric perforation induced by a chicken bone with hepatic perforation and abscess formation. Despite computed tomography scan (CT) showed possible perforation, laparotomy established the diagnosis.

CASE REPORT

A 62-year old woman presented in March 2005 to our emergency room with abdominal pain, fever and asthenia. She had a history of hypertension, gastro-oesophageal disease and hemorrhoids and was treated with ramipril and lansoprazole.

She had a 6-wk history of intermittent epigastric pain that progressively worsened, asthenia, anorexia and more recently developed mild fever. There was no history of chills, nausea, vomiting, thoracic pain, jaundice, respiratory or urinary complaints.

Physical examination revealed stable vital signs. And lung examination was unremarkable. Her abdomen was soft and tender to palpation but the liver was mildly tender and enlarged.

Laboratory investigations revealed a haemoglobin level of 10 g/dL, leukocytosis with granulocytosis (16 600/mm³ and 87%), C-reactive protein 24 mg/dL, elevated aspartate aminotransferase and alanine aminotransferase (43 and 35 IU/mL; normal < 31), γ -glutamyl transferase 93 UI/L (N < 55), with normal bilirubin and alkaline phosphatase. Plain radiographs of the chest and abdomen were normal. Abdomen ultrasound (US) revealed a hypoechoic lesion in the left lobe containing both gas and fluid. Contrast enhanced CT scan showed a large collection, measuring approximately 8.5 cm \times 7.0 cm, consistent with left-sided intra-hepatic abscess extending up to the gastric antrum, that presented parietal thickening (Figure 1). An abdominal RM did not rule out a liver tumor, but failed to show continuity with the gastric antrum (Figure 2).

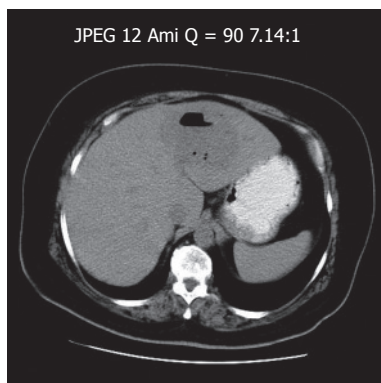


Figure 1 Contrast enhanced CT scan showing a low-density area with gas and fluid, measuring approximately 8.5 cm x 7.0 cm, consistent with left-sided intra-hepatic abscess.

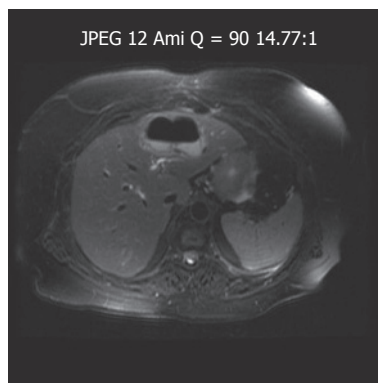


Figure 2 Abdominal RM demonstrating a large collection with gas and fluid.

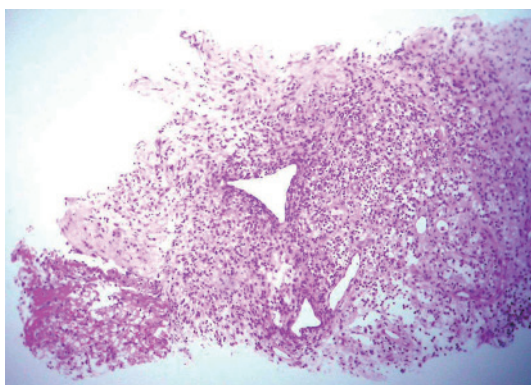


Figure 3 Biopsy of the liver abscess showing fibrosis, fibrin and acute inflammatory cells, consistent with abscess wall (HE).

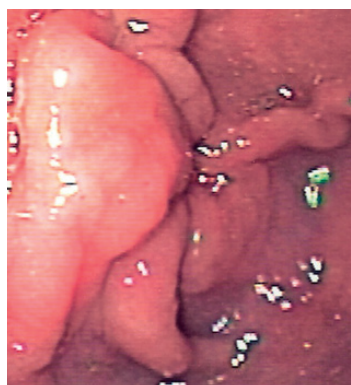


Figure 4 Upper GI endoscopy revealing a thickened gastric fold (pre-pyloric).

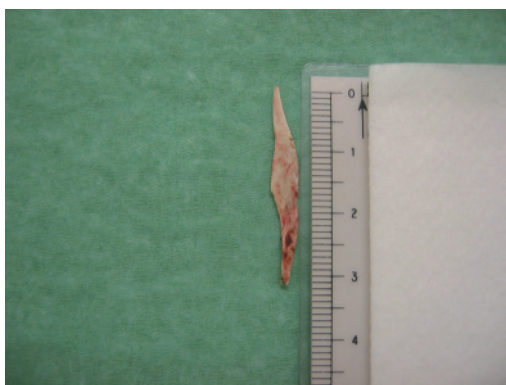

Figure 5 Removed foreign body (chicken bone, with 3.3 cm x 0.5 cm).

Using CT guidance, the hepatic abscess was drained percutaneously and pus and blood cultures were obtained. Microbiological examination of the drained fluid was negative and biopsies taken only revealed inflammatory process (Figure 3). Upper GI endoscopy revealed a pre-pyloric thickened fold (Figure 4), with normal histological evaluation. *Entamoeba histolytica* serology was negative.

The patient started on antibiotherapy (ampicillin, gentamicin and metronidazole) with clinical improvement. Four weeks later abdominal ultrasonography showed abscess size reduction (3 cm) and the patient was discharged and maintained antibiotic therapy.

Three weeks later the patient presented with fever,

abdominal pain and elevated C-reactive protein. Abdominal ultrasonography and CT scan showed enlargement of the abscess cavity (8.4 cm × 5.3 cm), which extended to the gastric antrum. Laparotomy was then performed and a foreign body (bone) was found embedded in the left lobe of the liver, resulting in a gastric antrum perforation (Figure 5). The bone was removed, the abscess drained, the stomach defect closed and a drain placed. The post-operative course was uneventful.

DISCUSSION

About 80%-90% of ingested foreign bodies pass through the gut without discovery within 1 wk^[1,2,4]. When symptoms arise they are usually secondary to obstruction^[1,2]. Gastrointestinal perforation has been reported in less than 1% of patients^[3-5] and the most commonly affected areas are the ileocecal and rectosigmoidal regions^[4,5] and duodenum^[2]. Development of hepatic abscess due to penetration induced by a foreign body is even more rare, the first case was published in 1898^[6]. Since then, the world literature has been increased, with 46 cases reported until now. The most common sites of perforation of the gut are stomach and duodenum^[5] which can be induced by sharp foreign bodies like fish bones, chicken bones, needles or toothpicks^[2,4,5,7] although pens or dental plates have also been reported^[7,8].

It is difficult to establish the time until the onset of symptoms as patients rarely recall the episode of ingestion^[1,3,4] and the migrating foreign body may remain silent until an abscess formation^[5].

Most patients have non specific symptoms such as

Table 1 World literature review of hepatic abscess induced by foreign bodies

Ref	Year	Author	Symptoms	Suffering period	Foreign body	Size (cm)	Penetration	Liver	Bacteria	Laparotomy	Treatment	Mortality
[1]	2003	Kanazana	Epigastralgia	1 mo	Toothpick	5.5	Stomach	Left lobe	Unknown	Yes	Abscess drained and removal of a small part of the liver	No
[2]	2000	Cheung	Epigastralgia, fever	3 mo	Toothpick	-	Stomach	Left lobe	Unknown	Yes	removal of the toothpick and a small part of the liver	No
[3]	2000	Broome	Epigastralgia, anorexia, fever	7 d	Chicken bone	4.0	Stomach	Left lobe	Unknown	Yes	Removal of the chicken bone and abscess drainage	No
[4]	1999	Horii	Fever, vomiting	2 wk	Fish bone	2.8	Unknown	Left lobe	Streptococcus constellatus	No	Percutaneous abscess drainage	No
[5]	2003	Chintamani	Fever, vomiting	1 yr	Needle	3.0	Unknown	Right lobe	Streptococcus pyogenes, E. coli	Yes	Removal of the needle and abscess drainage	No
[6]	2001	La Veja	Abdominal pain, vomiting	Unknown	Fish bone	2.5	Unknown	Right lobe	-	Autopsy		Yes
[7]	1999	Perkins	Fever, anaemia	2 wk	Pen	-	Duodenum	Right lobe	Streptococcus malleri (group C), Streptococcus malleri	No	Removal of the pen and abscess drainage	No
[8]	1983	Shaw	Fever		Dental plate	-	Descending colon		Unknown			
[9]	1997	Tsui			Clothespin, Tooth pick	-	Duodenum Stomach		Unknown			
[10]	1993	Chen	Epigastralgia, fever, weight loss	3 mo	Chicken bone	4.0	Duodenum	Left lobe	Unknown	Yes	Removal of the chicken bone and abscess drainage	No
[11]	2003	Bilimoria	Right upper abdominal pain, fever	Unknown	Toothpick	-	Sigmoid colon	Right lobe	Estreptococcus	Yes	Removal of the toothpick and abscess drainage	No
[12]	2004	Tomimori	Epigastralgia	4 wk	Fish bone	1.0	Stomach	Left lobe	Sreptococcus constellatus	Yes	Removal of the fish bone and abscess drainage	No
[13]	2001	Kessler	Abdominal pain	4 wk	Fish bone	Unknown	Duodenum	Left lobe	Eikenella corrodens	Yes	Removal of the fish bone and abscess drainage	No
[14]	2000	Paraskeva	Abdominal pain	4 mo	Fish bone	3.7	Sigmoid colon	Right lobe	Sreptococcus malleri	No	Removal of the fish bone	No
[15]	1999	Drnovsek	Abdominal pain, vomiting	1 d	Toothpick	Unknown	Duodenum	Both	Streptococcus viridens	Yes	Removal of the toothpick	No
[16]	1999	Guglielminetti			Toothpick	-	Stomach	Left lobe	Unknown	No	Endoscopic toothpick removal and percutaneous abscess drainage	
[17]	2002	Theodoropoulou	Right upper abdominal pain, fever, jaundice	3 d	Fish bone	5.5	Stomach	Left lobe	Unknown	Autopsy		Yes
[18]	1981	Wood	Fever, diarrhea	9 mo	Needle	-	Retrocecal appendix	Right lobe	Streptococcus viridens	Yes	Removal of the needle and abscess drainage	
[19]	2005	Starakis	Right upper abdominal pain, fever	3 wk	Chicken bone	-	Duodenum	Left lobe	Sreptococcus viridans, Eikenella corrodens	Yes	Removal of the chicken bone and abscess drainage	No
[20]	2003	Houli	Right upper abdominal pain, fever	2 wk	Chicken bone	3.5	Transverse colon	Right lobe	Streptococcus angiosus and mixed anaerobic flora	Yes	Abscess drainage, removal of the chicken bone and a small part of the liver	No
[21]	2001	Byard	Abdominal pain, fever	Several years	Chicken bone	3.8	Duodenum	Both	E. coli, mixed anaerobes and Candida albicans	Autopsy		Yes
[22]	1999	Chan	Abdominal pain, fever	Unknown	Fish bone	-	Stomach		Unknown	Yes	Removal of the fish bone, abscess drainage and parcial gastrectomy	No
[23]	1999	Tsai	Abdominal pain, fever		Fish bone	3.7	Stomach	Left lobe	Unknown	No	Abscess drainage and simple closure of the perforated hole	No
[24]	1992	Shuldais			Fish bone	-	Stomach		Unknown			
[25]	1991	Masunaga	Abdominal pain, fever, vomiting	1wk	Fish bone	4.0	Stomach	Left lobe	Unknown	Yes	Percutaneous abscess drainage, parcial gastrectomy and lateral segmentectomy	
[26]	1990	Allimant	Fever, astenia	3 wk	Toothpick	-	Stomach	Left lobe	Unknown	Yes	Drainage and removal of the tooth pick and a small part of the liver	No
[27]	1986	Penderson	Abdominal pain, shock	Unknown	Toothpick	3.5	Stomach	Left lobe	Unknown	Yes	Removal of the toothpick and abscess drainage	No
[28]	1988	Gonzalez	Abdominal pain, fever, jaundice, nausea	1 mo	Fish bone	Unknown	Stomach	Left lobe	Unknown	Yes	Removal of the fish bone and abscess drainage	No
[29]	1981	Rafizadeth	Low-grade fever	10 d	Toothpick	4.2	Duodenum	Left lobe	Estreptococcus	Yes	Removal of the toothpick and abscess drainage	No

[30]	1966	Aron	Asthenia, fever, jaundice	3 mo	Fish bone	2.2	Stomach	Right lobe	E. coli, Proteus	Yes	Removal of the toothpick, abscess drainage and piloroplasty	No
[31]	1971	Berk	Right upper abdominal pain	Several weeks	Chicken bone	4.0	Stomach	Left lobe	Unknown	Yes	Removal of the chicken bone, abscess drainage and partial gastrectomy	
[32]	1996	Acosta			Needle	-	Appendix		Unknown			
[33]	1971	Abel	None	Unknown	Needle	2.5	Stomach	Left lobe	Unknown	Yes	Removal of the needle and segmentectomy	No
[34]	1981	Tsuboi	Epigastralgia, weight loss	1 mo	Fish bone	4.7	Stomach	Left lobe	Unknown	Yes	Removal of the fish bone and abscess drainage	No
[35]	1984	Bloch	Fever, myalgia	2 wk	toothpick	4.5	Stomach or Duodenum	Left lobe	Streptococcus	Yes	Removal of the toothpick and abscess drainage	
[36]	1955	Griffiths	Septic shock	Unknown	Needle	4.0	Stomach	Right lobe	Unknown	Autopsy		Yes
	1955	Griffiths	Fever, vomiting	1 mo	Toothpick	6.0	Duodenum	Right lobe	Unknown	Autopsy		Yes
[37]	1990	Dugger	Fever, right upper abdominal pain	3 wk	Fish bone or Chicken bone	3.8	Stomach	Right lobe	E. coli, Proteus	Autopsy		
[38]	2005	Lee	Epigastralgia	5 d	Body piercing	5.0	Stomach	Left lobe	Klebsiella spp, Streptococcus milleri	Yes	Removal of the piercing, closure of the perforated hole and abscess drainage	No
	2005	Lee	Fever, epigastralgia, nausea, vomiting	1 wk	Fish bone	3.5	Stomach	Left lobe	Streptococcus milleri	Yes	Removal of the fish bone, closure of the perforated hole and abscess drainage	No
	2005	Lee	Epigastralgia	10 d	-	-	Stomach	Left lobe	Streptococcus milleri	Yes	Closure of the perforated hole	No
[39]	2005	Goh	Fever	5 d	Fish bone	3.0	Duodenum	Left lobe	Streptococcus milleri	Yes	Removal of the fish bone and abscess drainage	No
[40]	2006	Chiang	Right upper abdominal pain, fever	3 d	Toothpick	6.7	Duodenum	Right lobe	Staphylococcus aureus	No	Antibiotics (refused surgery)	No

abdominal pain, fever, vomiting, anorexia or weight loss^[4,5,9,10] which are features of a systemic response against an infection or abscess formation^[4]. Furthermore, the classical presentation of hepatic abscess (fever, abdominal pain and jaundice) is only present in a few cases^[5].

The results of routine laboratory studies are also non specific and unless the foreign body is radio-opaque it will not be identified on plain radiography^[3,4].

An abdominal US or CT scan is preferred techniques for the diagnosis, the latter is excellent in detection of foreign bodies due to its high resolution and accuracy^[1,2,4]. Endoscopy may be helpful when performed early, before the foreign body migration and mucosal healing^[2,11] (which happened in our patient). In addition, endoscopy does not allow examination of the mid-gut^[2]. Therefore, pre-operative diagnosis is difficult and a high degree of suspicion is required^[1,3].

We reviewed the world literature, and summarized it in Table 1. We found that fish bones were the most common foreign body and the stomach was the principal site of perforation. Abscess formation occurs more often on the left lobe. Microorganisms isolated on abscess or fluid cultures are usually part of the normal flora of human oropharynx^[4,5,7,12-14]. Prognosis depends on a quick diagnosis, not only for morbidity but also for mortality^[5-7].

Our clinical report is similar to the world literature and enhances the difficulty of diagnosing such an entity. Our patient who did not recall the ingestion, had non specific symptoms and laboratory results as well as US and CT showed a hepatic abscess on the left lobe and its fistulous track. The diagnosis was obtained after exploratory laparotomy. Considering all issues we suppose that the chicken bone perforated through the pylorus.

Hepatic abscess treatment includes aspiration and antibiotic therapy^[4]. Nevertheless if we suspect perforation of the gut caused by a foreign body or it is detected by

radiography, US or CT, surgery is the option^[15], although there are some descriptions of endoscopic^[4,14,17] or percutaneous^[4,16] removal. In our case surgery not only allowed to make a diagnosis but also treated it.

In conclusion, hepatic abscess diagnosis based on perforation of the gastrointestinal tract caused by a foreign body is difficult due to a variety of non specific symptoms and because patients are often unaware of the ingestion. In a hepatic abscess that does not respond to aspiration and antibiotic therapy we should look for an aetiology. Despite its rarity we should consider a foreign body and surgical therapy. Surgery still has a major role in the diagnosis and treatment of hepatic abscess induced by a foreign body although US and CT may establish it in some cases.

REFERENCES

- 1 **Kanazawa S**, Ishigaki K, Miyake T, Ishida A, Tabuchi A, Tanemoto K, Tsunoda T. A granulomatous liver abscess which developed after a toothpick penetrated the gastrointestinal tract: report of a case. *Surg Today* 2003; **33**: 312-314
- 2 **Cheung YC**, Ng SH, Tan CF, Ng KK, Wan YL. Hepatic inflammatory mass secondary to toothpick perforation of the stomach: triphasic CT appearances. *Clin Imaging* 2000; **24**: 93-95
- 3 **Broome CJ**, Peck RJ. Hepatic abscess complicating foreign body perforation of the gastric antrum: an ultrasound diagnosis. *Clin Radiol* 2000; **55**: 242-243
- 4 **Horii K**, Yamazaki O, Matsuyama M, Higaki I, Kawai S, Sakaue Y. Successful treatment of a hepatic abscess that formed secondary to fish bone penetration by percutaneous transhepatic removal of the foreign body: report of a case. *Surg Today* 1999; **29**: 922-926
- 5 **Chintamani**, Singhal V, Lubhana P, Durkhere R, Bhandari S. Liver abscess secondary to a broken needle migration--a case report. *BMC Surg* 2003; **3**: 8
- 6 **de la Vega M**, Rivero JC, Ruiz L, Suarez S. A fish bone in the liver. *Lancet* 2001; **358**: 982
- 7 **de la Vega M**, Rivero JC, Ruiz L, Suarez S. A fish bone in the liver. *Lancet* 2001; **358**: 982
- 8 **Shaw PJ**, Freeman JG. The antemortem diagnosis of pyogenic

- liver abscess due to perforation of the gut by a foreign body. *Postgrad Med J* 1983; **59**: 455-456
- 9 **Tsui BC**, Mossey J. Occult liver abscess following clinically unsuspected ingestion of foreign bodies. *Can J Gastroenterol* 1997; **11**: 445-448
 - 10 **Chintamani**, Singhal V, Lubhana P, Durkhere R, Bhandari S. Liver abscess secondary to a broken needle migration--a case report. *BMC Surg* 2003; **3**: 8
 - 11 **Bilimoria KY**, Eagan RK, Rex DK. Colonoscopic identification of a foreign body causing an hepatic abscess. *J Clin Gastroenterol* 2003; **37**: 82-85
 - 12 **Tomimori K**, Nakasone H, Hokama A, Nakayoshi T, Sakugawa H, Kinjo F, Shiraishi M, Nishimaki T, Saito A. Liver abscess. *Gastrointest Endosc* 2004; **59**: 397-398
 - 13 **Kessler AT**, Kourtis AP. Images in clinical medicine. Liver abscess due to *Eikenella corrodens* from a fishbone. *N Engl J Med* 2001; **345**: e5
 - 14 **Paraskeva KD**, Bury RW, Isaacs P. Streptococcus milleri liver abscesses: an unusual complication after colonoscopic removal of an impacted fish bone. *Gastrointest Endosc* 2000; **51**: 357-358
 - 15 **Drnovsek V**, Fontanez-Garcia D, Wakabayashi MN, Plavsic BM. Gastrointestinal case of the day. Pyogenic liver abscess caused by perforation by a swallowed wooden toothpick. *Radiographics* 1999; **19**: 820-822
 - 16 **Guglielminetti D**, Poddie DB. Liver abscess secondary to ingestion of foreign body. A case report. *G Chir* 1999; **20**: 453-455
 - 17 **Theodoropoulou A**, Roussomoustakaki M, Michalodimitrakis MN, Kanaki C, Kouroumalis EA. Fatal hepatic abscess caused by a fish bone. *Lancet* 2002; **359**: 977
 - 18 **Wood MK**, Harrison MR. 'A-pin-dicitis' and liver abscess. *JAMA* 1981; **246**: 940
 - 19 **Starakis I**, Karavias D, Marangos M, Psoni E, Bassaris H. A rooster's revenge: hepatic abscess caused by a chicken bone. *Eur J Emerg Med* 2005; **12**: 41-42
 - 20 **Houli N**, MacGowan K, Hosking P. Hepatic abscess complicating foreign body perforation of the transverse colon. *ANZ J Surg* 2003; **73**: 255-259
 - 21 **Byard RW**, Gilbert JD. Hepatic abscess formation and unexpected death: a delayed complication of occult intraabdominal foreign body. *Am J Forensic Med Pathol* 2001; **22**: 88-91
 - 22 **Chan SC**, Chen HY, Ng SH, Lee CM, Tsai CH. Hepatic abscess due to gastric perforation by ingested fish bone demonstrated by computed tomography. *J Formos Med Assoc* 1999; **98**: 145-147
 - 23 **Tsai JL**, Than MM, Wu CJ, Sue D, Keh CT, Wang CC. Liver abscess secondary to fish bone penetration of the gastric wall: a case report. *Zhonghua Yixue Zazhi (Taipei)* 1999; **62**: 51-54
 - 24 **Shuldais AK**, Sumin AV, Tkhorzhevskii BB. Pyogenic hepatic abscess developing after perforation of the stomach by a fish bone. *Klin Khir* 1992; 75-76
 - 25 **Masunaga S**, Abe M, Imura T, Asano M, Minami S, Fujisawa I. Hepatic abscess secondary to a fishbone penetrating the gastric wall: CT demonstration. *Comput Med Imaging Graph* 1991; **15**: 113-116
 - 26 **Allimant P**, Rosburger C, Zeyer B, Frey G, Morel E, Bietiger M, Dalcher G. An unusual cause of hepatic abscess. *Ann Gastroenterol Hepatol (Paris)* 1990; **26**: 5-6
 - 27 **Pedersen VM**, Geerdtsen JP, Bartholdy J, Kjaergaard H. Foreign body perforation of the gastrointestinal tract with formation of liver abscess. *Ann Chir Gynaecol* 1986; **75**: 245-246
 - 28 **Gonzalez JG**, Gonzalez RR, Patino JV, Garcia AT, Alvarez CP, Pedrosa CS. CT findings in gastrointestinal perforation by ingested fish bones. *J Comput Assist Tomogr* 1988; **12**: 88-90
 - 29 **Rafizadeh F**, Silver H, Fieber S. Pyogenic liver abscess secondary to a toothpick penetrating the gastrointestinal tract. *J Med Soc N J* 1981; **78**: 377-378
 - 30 **Aron E**, Roy B, Groussin P. Abscess of the liver caused by fish bone. *Presse Med* 1966; **74**: 1957-1958
 - 31 **Berk RN**, Reit RJ. Intra-abdominal chicken-bone abscess. *Radiology* 1971; **101**: 311-313
 - 32 **Acosta S**, Lantz L. A case report. A pin in the appendix caused hepatic abscess. *Lakartidningen* 1996; **93**: 4278
 - 33 **Abel RM**, Fischer JE, Hendren WH. Penetration of the alimentary tract by a foreign body with migration to the liver. *Arch Surg* 1971; **102**: 227-228
 - 34 **Tsuboi K**, Nakajima Y, Yamamoto S, Nagao M, Nishimura K, Yoshii M. A case of an intrahepatic fish bone penetration--possibility of the preoperative diagnosis by CT scan (author's transl). *Nippon Geka Hokan* 1981; **50**: 899-903
 - 35 **Bloch DB**. Venturesome toothpick. A continuing source of pyogenic hepatic abscess. *JAMA* 1984; **252**: 797-798
 - 36 **Griffiths FE**. Liver abscess due to foreign-body migration from the alimentary tract; a report of two cases. *Br J Surg* 1955; **42**: 667-668
 - 37 **Dugger K**, Lebby T, Brus M, Sahgal S, Leikin JB. Hepatic abscess resulting from gastric perforation of a foreign object. *Am J Emerg Med* 1990; **8**: 323-325
 - 38 **Lee KF**, Chu W, Wong SW, Lai PB. Hepatic abscess secondary to foreign body perforation of the stomach. *Asian J Surg* 2005; **28**: 297-300
 - 39 **Goh BK**, Yong WS, Yeo AW. Pancreatic and hepatic abscess secondary to fish bone perforation of the duodenum. *Dig Dis Sci* 2005; **50**: 1103-1106
 - 40 **Chiang TH**, Liu KL, Lee YC, Chiu HM, Lin JT, Wang HP. Sonographic diagnosis of a toothpick traversing the duodenum and penetrating into the liver. *J Clin Ultrasound* 2006; **34**: 237-240

S- Editor Liu Y L- Editor Wang XL E- Editor Zhou T