

Urol Ann. 2017 Jan-Mar; 9(1): 89–91.

doi: [10.4103/0974-7796.198886](https://doi.org/10.4103/0974-7796.198886)

PMCID: PMC5308049

## **Epididymal metastasis from prostate adenocarcinoma: An unusual and challenging diagnosis suspected in gallium-68 prostate-specific membrane antigen-positron emission tomography/computed tomography and histologically confirmed**

[Sofia Santos-Lopes](#),\* [João Lobo](#),<sup>1,\*</sup> [Rui Henrique](#),<sup>1,#</sup> and [Jorge Oliveira](#)<sup>2,#</sup>

**Address for correspondence:** Dr. Sofia Santos-Lopes, Department of Urology, Hospital Prof. Doutor Fernando Fonseca, IC 19, 2720-276, Amadora, Portugal. E-mail: [tp.eduas-nim.ffh@sepol.aifos](mailto:tp.eduas-nim.ffh@sepol.aifos)

\*Sofia Santos-Lopes and João Lobo authors equally contributed

#Rui Henrique and Jorge Oliveira Joint senior authors

Received 2016 Oct 8; Accepted 2016 Nov 29.

**Copyright** : © 2017 Urology Annals

This is an open access article distributed under the terms of the Creative Commons Attribution-NonCommercial-ShareAlike 3.0 License, which allows others to remix, tweak, and build upon the work non-commercially, as long as the author is credited and the new creations are licensed under the identical terms.

### **Abstract**

### **INTRODUCTION**

Prostate adenocarcinoma (PCa) is the second most frequent male neoplasm worldwide.[1] Metastatic spread frequently affects bone, lung, and liver. However, testicular metastases represented solely 0.5% of PCa metastases in an autopsy study of 1589 patients, and none was located in the epididymis.[2] The first report of epididymal metastasis from PCa dates from 1944, and the majority of cases diagnosed ever since were incidentally found during surgical castration.[3,4,5] We conducted a MEDLINE search, and only 26 cases have been reported worldwide.

Herein, we report a case of this rare route of PCa dissemination, focusing on its diagnostic challenges and pitfalls.

### **CASE REPORT**

A 69-year-old Caucasian man, with a medical history of colorectal adenocarcinoma at the age 37 years, was subject to radical prostatectomy and adjuvant radiation therapy at the age 63 years due to PCa, pT3N0M0R1-Gleason score 8 (5 + 3). Other comorbidities included high blood pressure and radiation-induced proctitis.

Five years after treatment for PCa, biochemical recurrence was depicted. Bone-scan and abdominopelvic computed tomography did not disclose any metastatic lesion or local recurrence. As serum prostate-specific antigen (PSA) continued to rise, reaching 20 ng/mL, gallium-68 prostate-specific membrane antigen-positron emission tomography/computed tomography (<sup>68</sup> Ga-PSMA PET/CT) was performed, showing high uptake in the left testis and retrovesical space [Figure 1]. A firm elastic nodularity with 2 cm was then found on clinical examination of the left epididymis, but the patient referred that it was an old lesion. Pelvic magnetic resonance confirmed the presence of a 2.2 cm solid, heterogeneous nodule, hypointense in T2 sequence, with arterial vascularization [Figure 2]. Due to the uncertainty about the neoplastic or inflammatory origin of the nodule, left radical orchiectomy was performed.

Macroscopic examination of the surgical specimen revealed a 1.8 cm × 1.4 cm solid, rubbery, whitish nodule in the epididymal tail. The lesion was confined to the epididymis, sparing the testicular parenchyma [Figure 3a]. On histological examination, the lesion was composed of malignant glands infiltrating around the epididymal ducts [Figure 3b] as well as the adipose tissue/neurovascular structures [Figure 3c]. Immunohistochemical staining for PSA demonstrated strong diffuse cytoplasmic immunoreactivity in the neoplastic glands [Figure 3d].

Postoperative PSA was 62.70 ng/mL and palliative androgen deprivation therapy was started. The patient remains asymptomatic 4 months after surgery.

## DISCUSSION

---

Epididymal masses are, overall, rare findings. Differential diagnosis includes both neoplastic (primary and metastatic) and nonneoplastic lesions. Benign tumors (such as lipomas and adenomatoid tumors) and several tumor-like lesions (including epididymal cysts and epididymitis) may truly simulate malignancies; thus, clinical awareness of these entities is fundamental. Concerning primary malignant tumors, sarcomas are among the most frequently arising in the paratesticular area.[6] Further, testicular tumors may show extension into paratesticular structures such as epididymis, which has implications on staging. Classical criteria used for favoring a metastatic tumor over a testicular primary include age >50 years, bilaterality, prior history of neoplasia, an infrequent morphology for a primary testicular/paratesticular tumor, lymphovascular invasion, and an intertubular growth pattern; all criteria were met in our patient, except bilateral involvement. In addition, immunohistochemical studies might be valuable in difficult cases, as proved to be in the current case, where the strong and diffuse cytoplasmic immunoreactivity of the tumor cells for PSA proved the prostatic origin.

Metastatic tumors to the epididymis are exceedingly rare and have been reported to originate not only from the colon[7] and prostate[8] (the patient's previous neoplasms) but also from the kidney and bile ducts.[9] In a patient with a medical

history of both colorectal and PCas, a metastatic origin for the epididymal mass should also be suspected and adequate clinical evaluation performed.

There are few previous reports of PCa metastases to the epididymis. Most cases were asymptomatic and incidentally discovered at autopsy or after bilateral orchiectomy for castration purposes. Regarding dissemination routes, arterial embolization, retrograde venous extension, lymphatic extension, or retrograde intraluminal spread through the vas deferens have been proposed. In our case, as in other reports, the latter mechanism seems less likely as no intraluminal invasion was depicted, with tumor cells externally infiltrating around the epididymal ducts.[3]

The diagnosis of biochemical failure is quite a challenge to urologists and oncologists, and many imaging methods of detecting it have been proposed.<sup>68</sup> Ga-PSMA PET/CT uses PSMA, a membrane-bound enzyme that has significantly elevated expression in prostate cancer cells, compared to benign prostatic tissue, and is one of the most recent advances in this field. Its value relies on the higher detection rates for recurrent disease when compared to other imaging modalities, even for patients with PSA values as low as 0.5 ng/mL.[10] In our case, in particular, this technique was crucial for the diagnosis of the epididymal metastasis as all the previous examinations were nondiagnostic. Prospective trials and clinical guidelines for this new technique are still missing; however, <sup>68</sup> Ga-PSMA PET/CT could help identifying oligometastatic disease or local recurrence in patients with low PSA values and thus have impact on PCa management.

Due to its rarity, the prognostic impact of this kind of metastasis is not known, thus precluding definitive statements regarding the most adequate therapeutic strategy.[4,5] Nevertheless, the case presented herein emphasizes the need for accurate diagnosis, which may require orchiectomy. Importantly, new imaging modalities, such as <sup>68</sup>Ga-PSMA PET/CT, may improve patients' follow-up by increasing the accuracy of identification of metastatic lesions or local recurrence, allowing for timely therapeutic decision.

## **CONCLUSION**

---

Despite constituting rare events, metastatic tumors should be considered in the differential diagnosis of epididymal masses, especially in older patients with a medical history of neoplasia. An accurate diagnosis is fundamental since it has implications both on prognosis and on therapeutic management and requires a good clinical, analytical, and pathological correlation since the disease can be quite silent. Only by being aware of this clinical scenario, can clinicians clinch this diagnosis and timely intervene to improve their patients' quality of life and survival.

## **Financial support and sponsorship**

Nil.

## **Conflicts of interest**

There are no conflicts of interest.

## REFERENCES

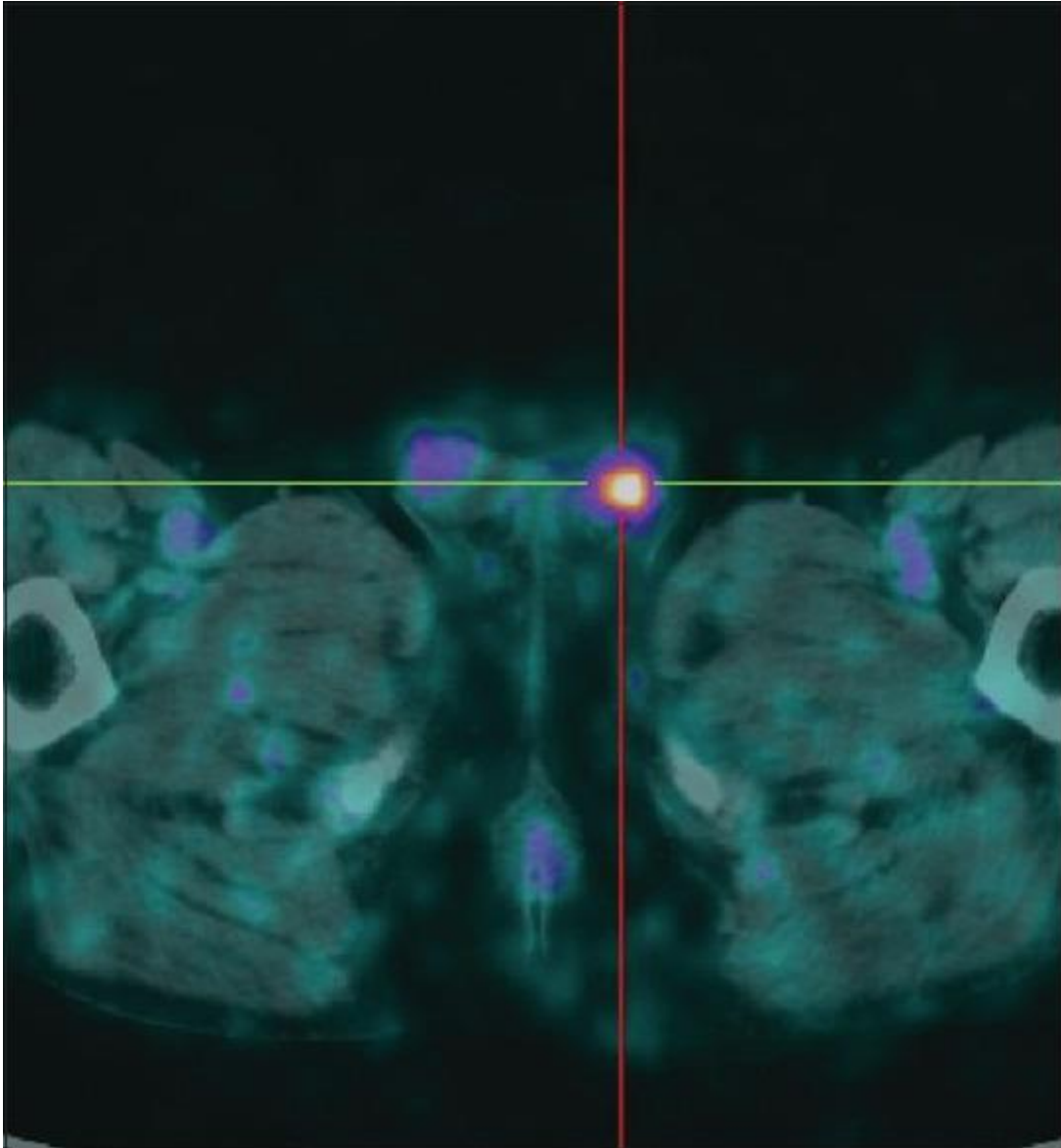
---

1. Ferlay J, Soerjomataram I, Dikshit R, Eser S, Mathers C, Rebelo M, et al. Cancer incidence and mortality worldwide: Sources, methods and major patterns in GLOBOCAN 2012. *Int J Cancer*. 2015;136:E359–86. [PubMed: 25220842]
2. Bubendorf L, Schöpfer A, Wagner U, Sauter G, Moch H, Willi N, et al. Metastatic patterns of prostate cancer: An autopsy study of 1,589 patients. *Hum Pathol*. 2000;31:578–83. [PubMed: 10836297]
3. Rizk CC, Scholes J, Chen SK, Ward J, Romas NA. Epididymal metastasis from prostatic adenocarcinoma mimicking adenomatoid tumor. *Urology*. 1990;36:526–30.[PubMed: 1701066]
4. Addonizio JC, Thelmo W. Epididymal metastasis from prostatic carcinoma. *Urology*. 1981;18:490–1. [PubMed: 7314342]
5. Zhang J, Dong M, Hu X, Liu L, Li S, Li C, et al. Prostatic adenocarcinoma presenting with metastases to the testis and epididymis: A case report. *Oncol Lett*. 2016;11:792–4. [PMCID: PMC4727079] [PubMed: 26870285]
6. Khandeparkar SG, Pinto RG. Histopathological spectrum of tumor and tumor-like lesions of the paratestis in a Tertiary Care Hospital. *Oman Med J*. 2015;30:461–8.[PMCID: PMC4678445] [PubMed: 26674546]
7. Janeiro Pais JM, Busto Castañón L, Barbagelata López A, Diaz-Reixa JP, Romero Selás E, Casas Agudo VP, et al. Metastasis of colon adenocarcinoma to the epididymis and spermatic cord. *Arch Esp Urol*. 2006;59:746–8. [PubMed: 17078403]
8. Heman-Ackah C, Fox AT, El-Jabbour J. Epididymal metastasis from carcinoma of the prostate. *ScientificWorldJournal*. 2004;4(Suppl 1):150–1. [PubMed: 15349541]
9. Bennett VS, Bailey DM. Cholangiocarcinoma presenting as a solitary epididymal metastasis: A case report and review of the literature. *Diagn Pathol*. 2007;2:33.[PMCID: PMC2000863] [PubMed: 17760973]
10. Maurer T, Eiber M, Schwaiger M, Gschwend JE. Current use of PSMA-PET in prostate cancer management. *Nat Rev Urol*. 2016;13:226–35. [PubMed: 26902337]

## Figures and Tables

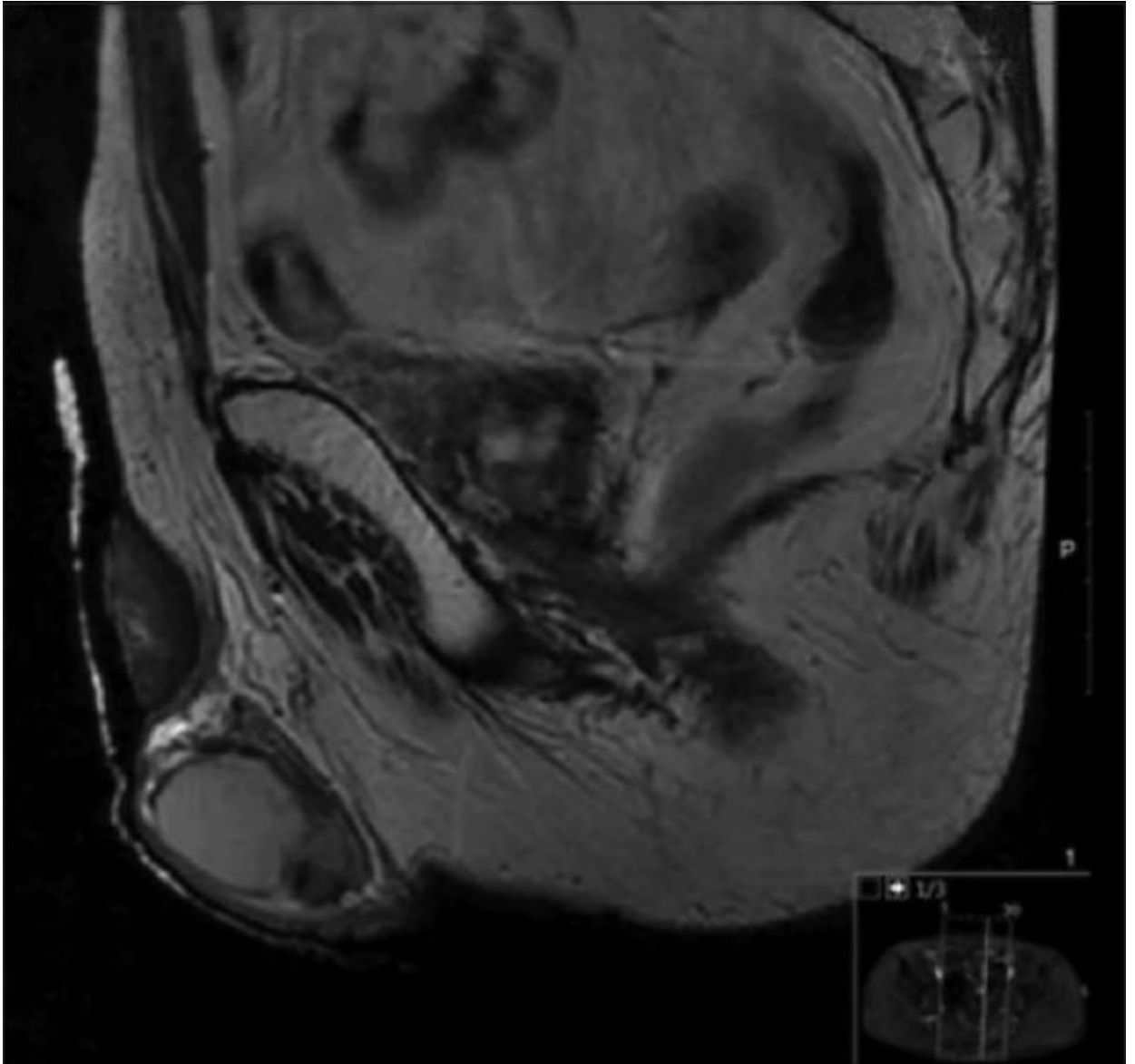
---

### Figure 1



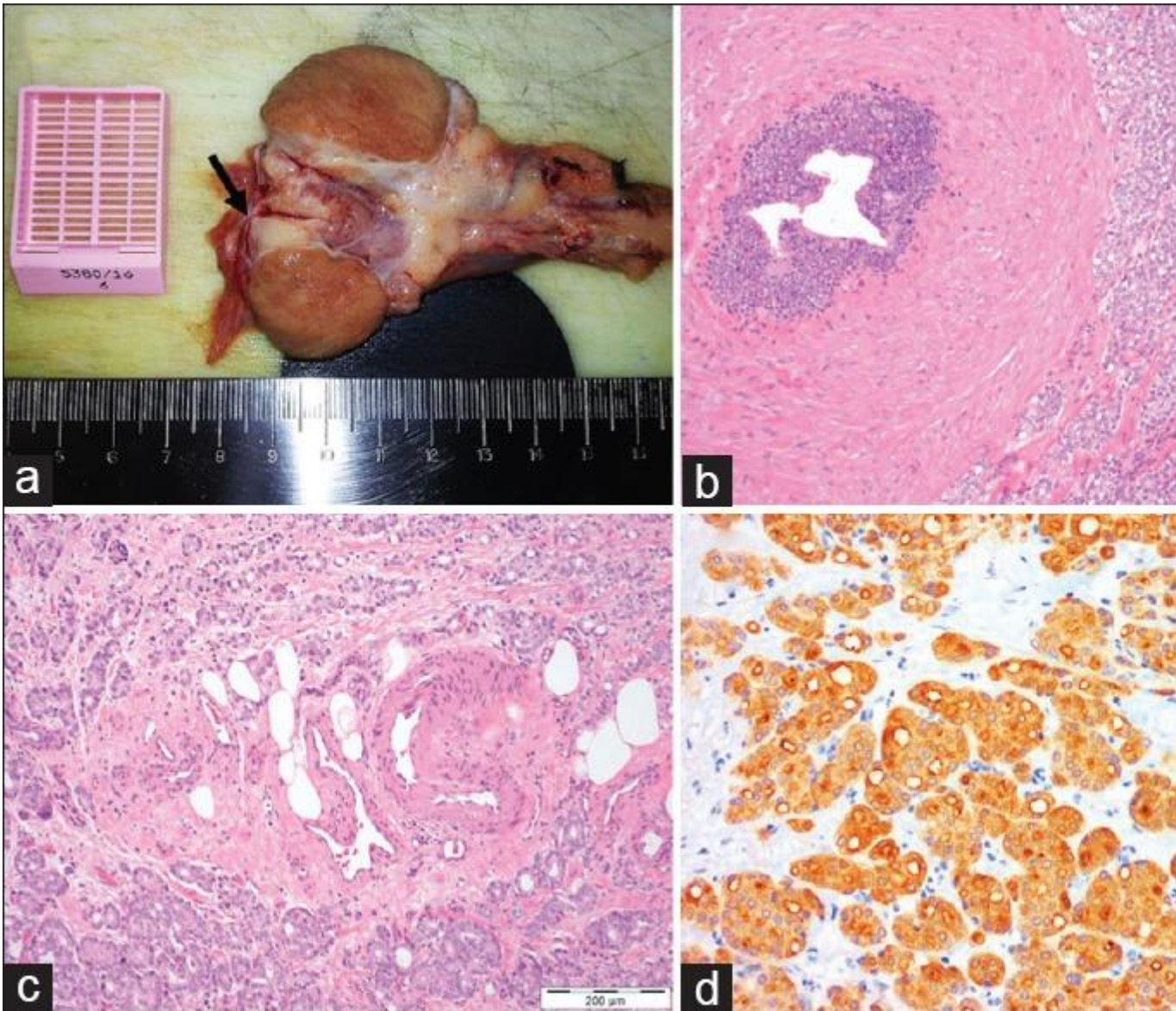
Gallium-68 prostate-specific membrane antigen-positron emission tomography/computed tomography clearly showing tracer uptake in the left testis, in correlation with the pathological findings

**Figure 2**



Pelvic magnetic resonance on sagittal view confirming the presence of a 2.2 cm nodule circumscribed to the left epididymis, hypointense in T2 sequence

**Figure 3**



Histopathological examination of the radical left orchiectomy specimen. (a) Macroscopy: Nodule in epididymal tail (arrow). (b and c) Histology (H and E,  $\times 100$ ): Epididymal metastasis infiltrating epididymal ducts (b) and neurovascular structures (c). (d) Immunohistochemistry (PSA,  $\times 200$ ): Diffuse cytoplasmic immunoreactivity