

Case 9614

Renal biopsy complication and treatment

Cabral P¹, Donato P², Caseiro-Alves F²

(1) Department of Radiology of Hospital Prof. Dr. Fernando Fonseca, Amadora, Portugal

(2) Department of Radiology of Hospital Universidade Coimbra, Coimbra, Portugal

Section: Interventional Radiology

Published: 2011, Nov. 4

Patient: 53 year(s), female

Authors' Institution

Hospital Prof Doutor Fernando Fonseca;
Rua Joaquim Rocha Cabral 16 - 4º B
1600-086 Lisboa, Portugal;
Email:pvaldezpt@yahoo.com

Clinical History

A 53-year-old woman with nephrotic syndrome under investigation is submitted to an ultrasound guided right kidney biopsy. There were no immediate complications reported. Approximately 24h after the procedure the patient complains of right lumbar pain without haematuria and a decrease in the haematocrit and haemoglobin levels is noticed.

Imaging Findings

An ultrasound study (Fig. 1) was the first examination to be carried out showing a heterogeneous liquid collection in the right perirenal space, postero-lateral to the kidney, measuring 9 cm in diameter, raising the possibility of a post biopsy haematoma given the clinical context. It was followed by a CE-CT (Fig. 2) revealing two large haematomas, one in the right lateral abdominal wall and another in the right perirenal space. Active contrast extravasation could be

identified in both haematomas suggesting active haemorrhage.

The patient was immediately taken to the angiography room and active haemorrhage from a right lumbar artery and from a distal interlobular branch of the lower division of the right renal artery were documented (Fig. 3, 5a), followed by successful embolisation. The lumbar artery was embolised using two 3 x 30 mm (diameter x length) coils and the renal arterial branch using 500-700 µm microspheres (Fig. 4ab, 5b).

Discussion

Renal haematomas are the most prevalent complication after percutaneous kidney biopsies but fortunately most of the times are self-limited situations without the need for active intervention [1]. Other complications like clinically significant arteriovenous fistula, infections or pneumothorax are considerably less frequent and life threatening complications are exquisitely rare being less than 0.1% [2]. These figures have improved much in recent years mainly due to the widespread use of ultrasound guidance and automated-gun biopsy devices [3].

One should be especially cautious with patients on anticoagulants or antiplatelet agents in spite of the lower risk reported in the literature for this last group. Extra care should be taken for patients with known haemorrhagic dyscrasias which have a very high risk of complicated bleeding after the procedure and should therefore be managed accordingly [4].

Persistent abdominal or lumbar pain, gross haematuria, new onset of oliguria, tachycardia and hypotension are the clinical indicators of major haemorrhage after a renal biopsy. At the slightest suspicion a kidney ultrasound can exclude the presence of a perirenal or subcapsular haematoma. The CT can help us characterise and precisely locate any ultrasound finding. With the use of contrast enhancement, active haemorrhagic leaks can be documented allowing the physician to decide whether a more aggressive approach is needed [5, 6].

We should be aware of false negative CT studies with slow bleeding below 0, 5ml/min [7].

The definitive diagnosis is made by selective renal arteriography.

A radiological interventional approach for acute bleeding complications after a percutaneous renal biopsy is currently, where available, the preferred choice, sparing patients nephrectomy. If not available, surgery will be the only option and nephrectomy inevitably necessary, partial or total, depending on the location of the bleeding artery [5, 6, 7].

The procedure can be extremely effective and even surprisingly simple in experienced hands. The Seldinger technique is used to catheterize the femoral artery, then a guide wire is passed into the renal artery and superselective catheterization of the most distal bleeding vessel is attempted. Next, transcatheter embolisation is performed and the immediate control of the bleeding is usually achieved. Metallic microcoils and acrylic microspheres are the most often used embolisation agents [8].

After a successful procedure a wedge-shaped infarct area can be observed with CE-CT and angiographically (Fig. 6).

In this case the percutaneous approach proved to be the best choice. The patient rapidly recovered. An abdominal CE-CT was repeated one week after the intervention and reduction of the haematomas without active bleeding was already evident.

Final Diagnosis

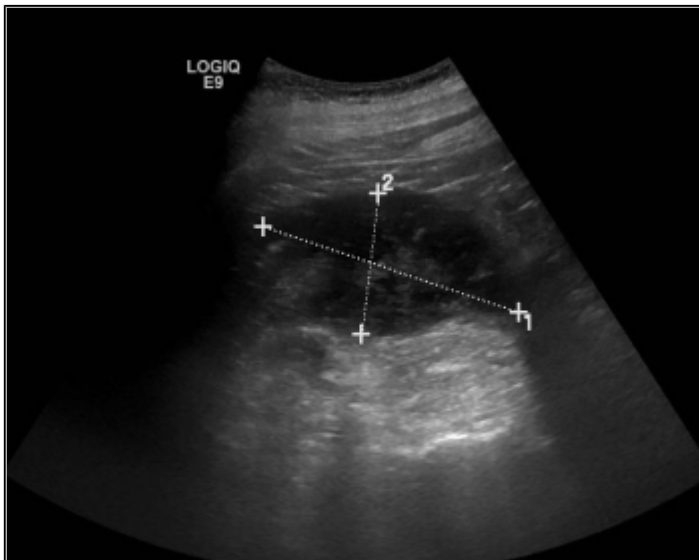
Post renal biopsy active haemorrhage from renal and lumbar artery

Differential Diagnosis List

Post biopsy haematoma without active haemorrhage, Post biopsy arterio-venous fistula, Perirenal abscess

Figures

Figure 1 Renal ultrasound



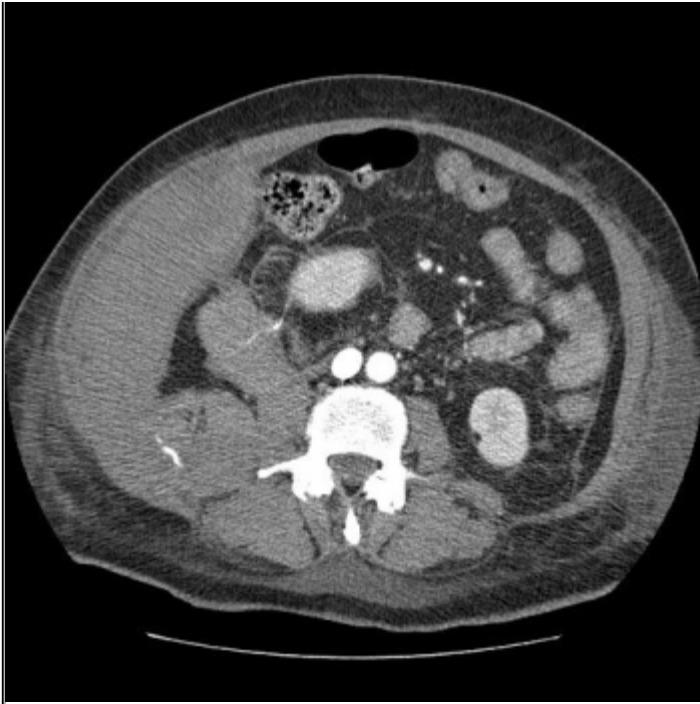Heterogeneous liquid collection in the right flank suggestive of a post-biopsy haematoma.

© Department of Radiology of Hospital Universidade Coimbra

Area of Interest: Kidney;
Imaging Technique: Ultrasound;
Procedure: Diagnostic procedure;
Special Focus: Haemorrhage;

Figure 2 Abdominal CE-CT

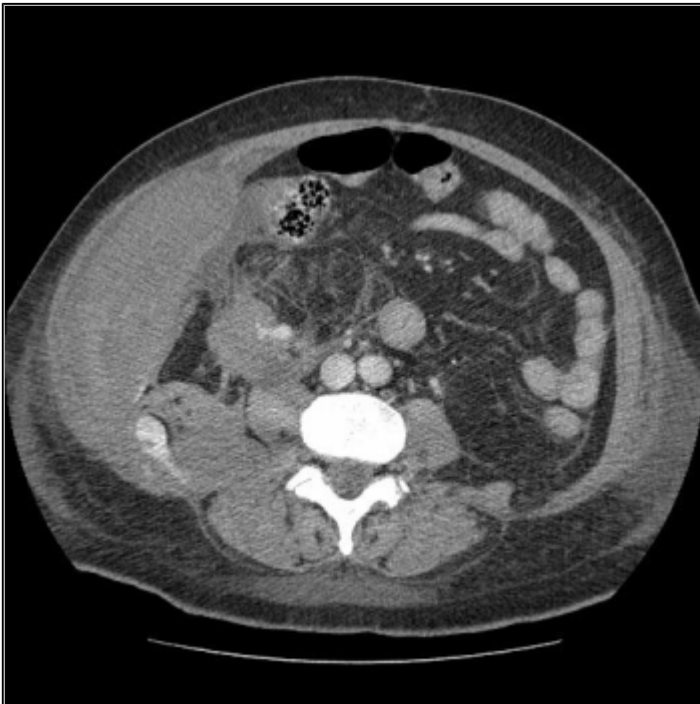



Axial arterial acquisition. Two haematomas are seen in the right postero-lateral abdominal wall and in the perirenal space pushing the kidney anterior and medially. In both, a linear image of contrast extravasation is clearly identified.

© Department of Radiology of Hospital Universidade Coimbra

Area of Interest: Kidney;
Imaging Technique: CT;
Procedure: Diagnostic procedure;
Special Focus: Haemorrhage;

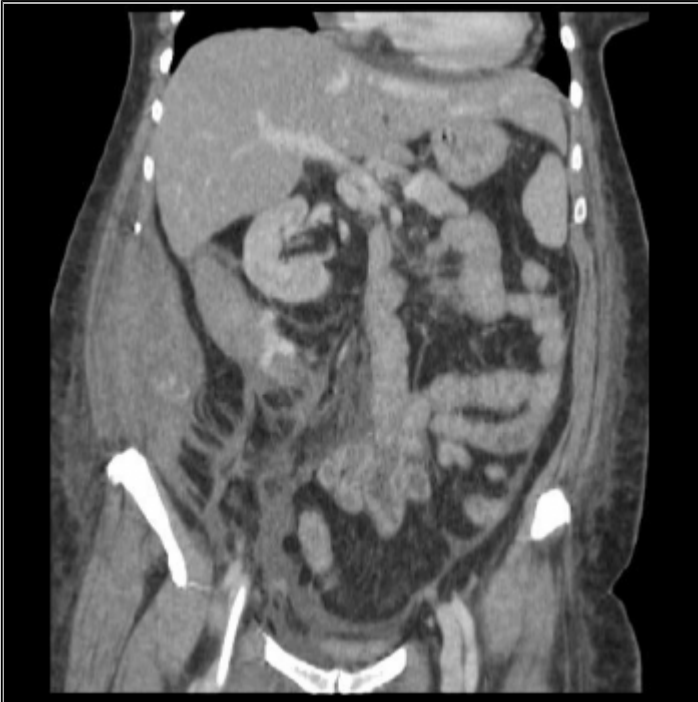

Portal phase CE acquisition showing that the contrast leakage increases due to active haemorrhage.

© Department of Radiology of Hospital Universidade Coimbra

Area of Interest: Kidney;

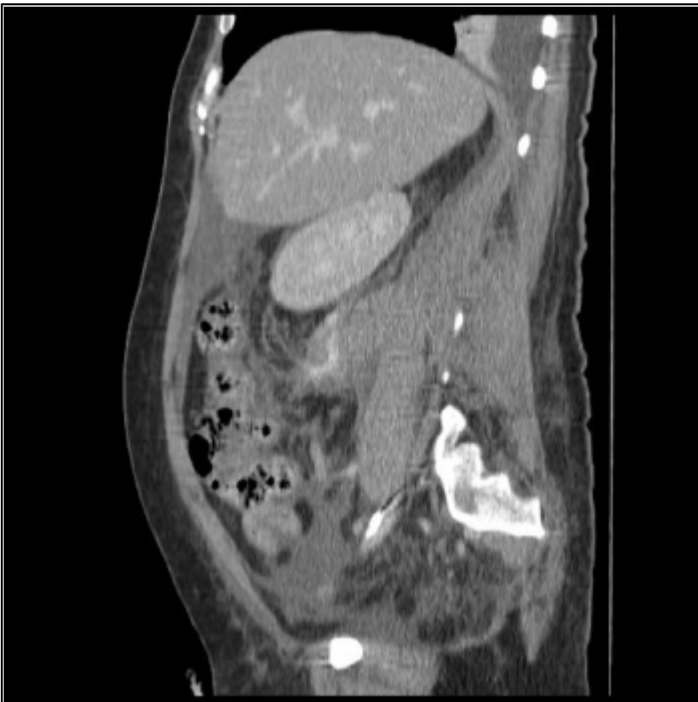Imaging Technique: CT;
Procedure: Diagnostic procedure;
Special Focus: Haemorrhage;



In this CE coronal reconstruction the active haemorrhagic leak can be seen near the lower pole of the right kidney corresponding to the biopsy needle insertion point.

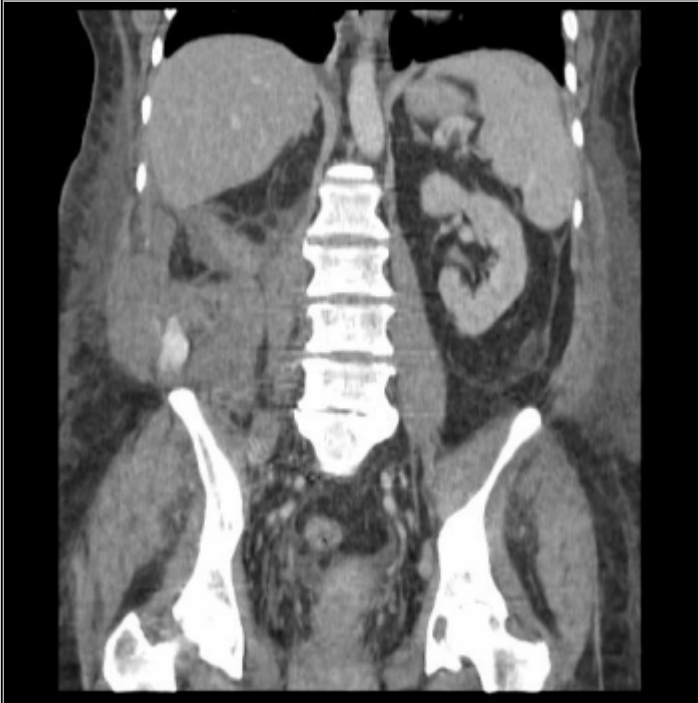© Department of Radiology of Hospital Universidade Coimbra

Area of Interest: Kidney;
Imaging Technique: CT;
Procedure: Diagnostic procedure;
Special Focus: Haemorrhage;



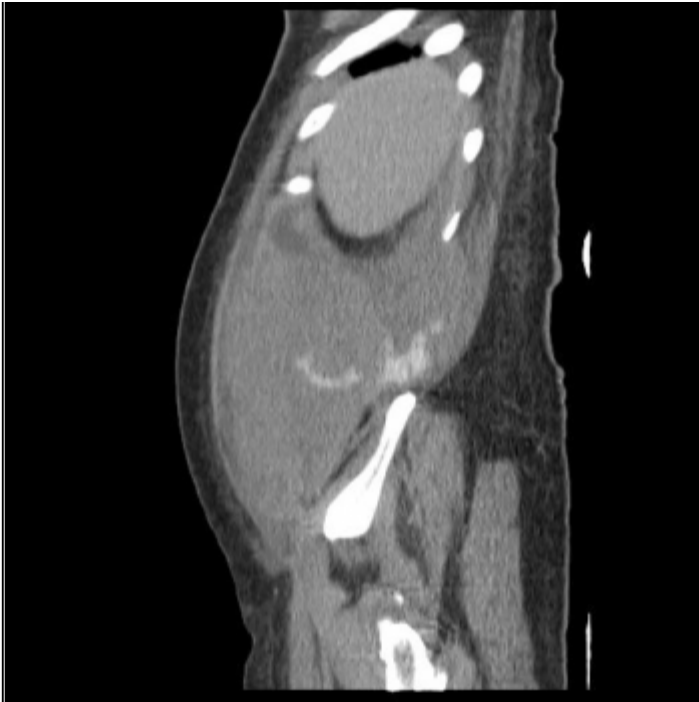Sagittal reconstruction of the same aspects in 2b and 2c. Haemorrhagic leak of the posterior lower pole of the right kidney.

Area of Interest: Kidney;
Imaging Technique: CT;
Procedure: Diagnostic procedure;
Special Focus: Haemorrhage;



In this further CE coronal reconstruction a second active haemorrhagic leak can be seen adjacent to the postero-lateral right abdominal wall, just above the iliac crest.

Area of Interest: Kidney;
Imaging Technique: CT;
Procedure: Diagnostic procedure;
Special Focus: Haemorrhage;

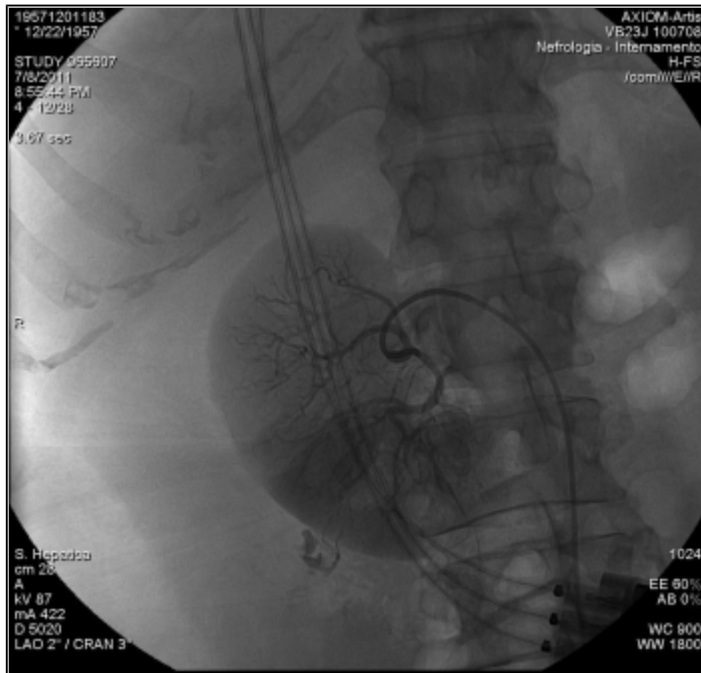


Sagittal reconstruction of the same aspects in 2b and 2e. Haemorrhagic leak of the postero-lateral abdominal wall.

© Department of Radiology of Hospital Universidade Coimbra

Area of Interest: Kidney;
Imaging Technique: CT;
Procedure: Diagnostic procedure;
Special Focus: Haemorrhage;

Figure 3 Angiography

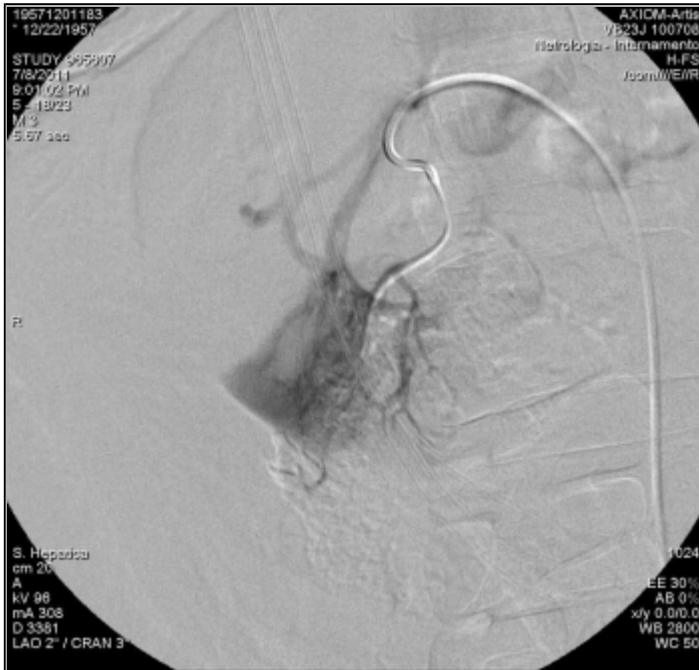

Right kidney renogram. Regular opacification of the kidney with contrast leaking to the perirenal space.

© Department of Radiology of Hospital Universidade de Coimbra

Area of Interest: Interventional vascular; Kidney;
Imaging Technique: Catheter arteriography;
Procedure: Diagnostic procedure;
Special Focus: Haemorrhage;

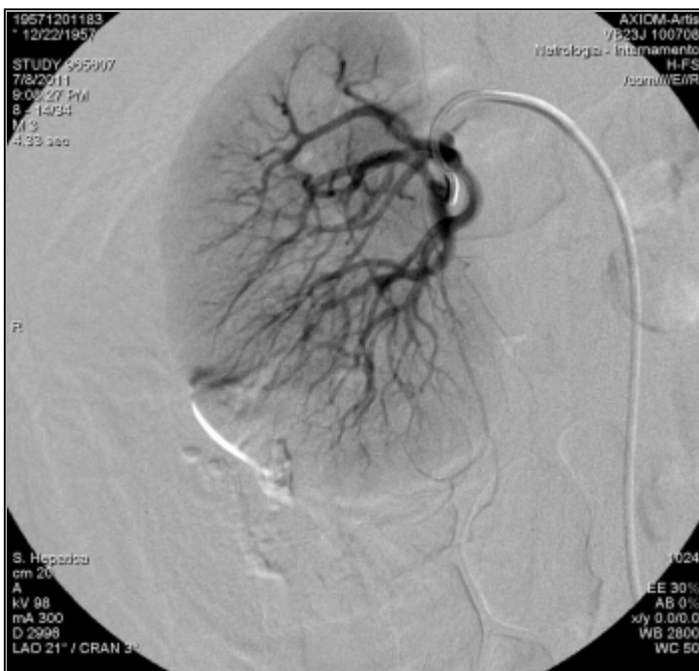Figure 4 Angiography



The actively bleeding distal intralobular branch of the renal artery was selectively catheterised with a microcatheter and embolised using microspheres.

© Department of Radiology of Hospital Universidade Coimbra

Area of Interest: Interventional vascular; Kidney;
Imaging Technique: Catheter arteriography;
Procedure: Embolisation;
Special Focus: Haemorrhage;

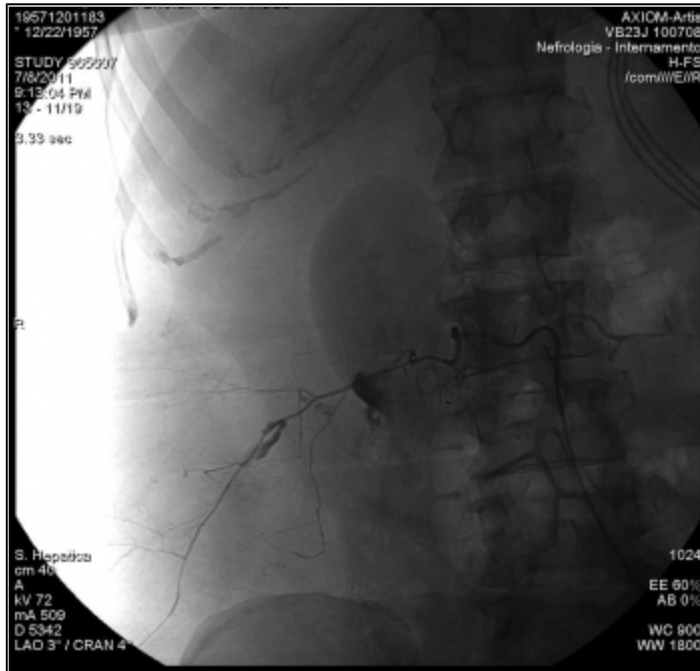


After the procedure the haemorrhage was successfully stopped. The embolised segment in the lower third of the kidney can be identified as a non-perfused peripheral wedge-shaped region.

© Department of Radiology of Hospital Universidade Coimbra

Area of Interest: Interventional vascular; Kidney;
Imaging Technique: Catheter arteriography;
Procedure: Embolisation;
Special Focus: Haemorrhage;

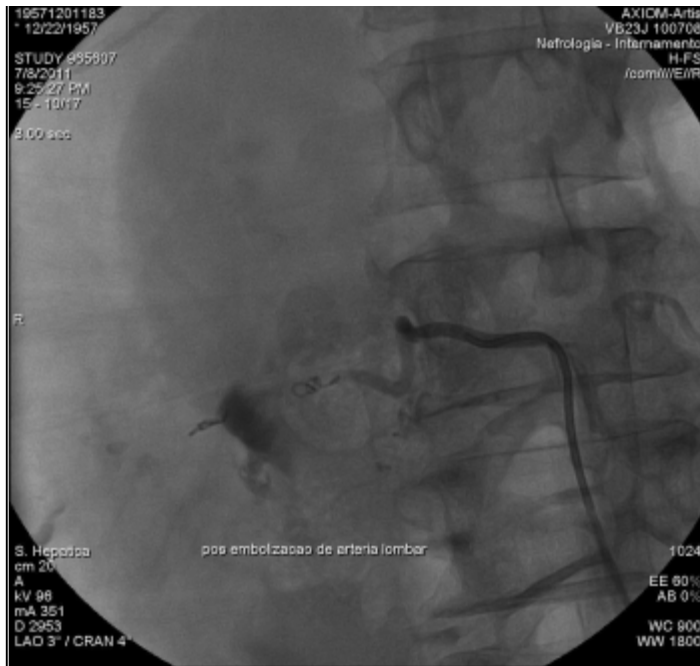Figure 5 Angiography



The lumbar artery responsible for the lateral abdominal haematoma was also found and selectively catheterised. The active haemorrhage was documented.

© Department of Radiology of Hospital Universidade Coimbra

Area of Interest: Interventional vascular; Kidney;
Imaging Technique: Catheter arteriography;
Procedure: Embolisation;
Special Focus: Haemorrhage;

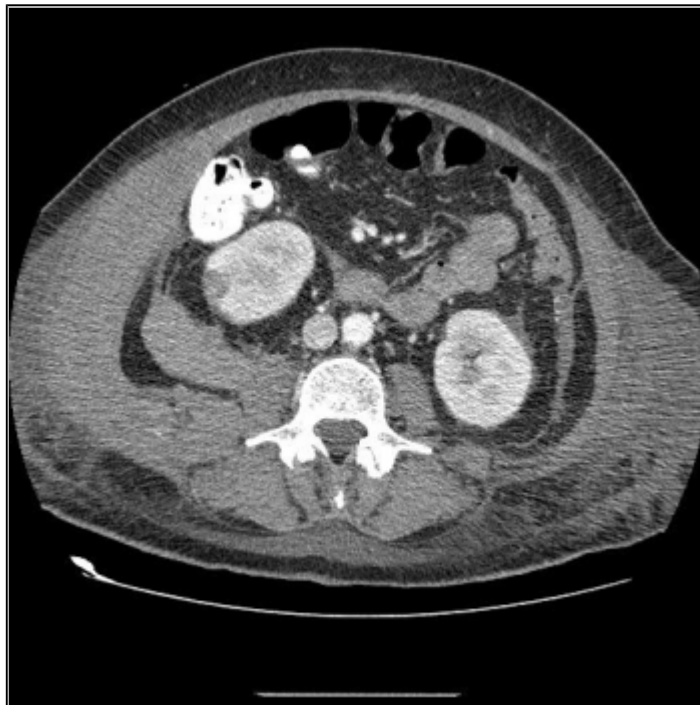

Embolisation of the bleeding lumbar artery with two coils stopped the haemorrhage. Notice that pooled contrast outside the artery persists despite the successful placement of the coils but does not increase with additional contrast injection.

© Department of Radiology of Hospital Universidade Coimbra

Area of Interest: Interventional vascular; Kidney;
 Imaging Technique: Catheter arteriography;
 Procedure: Embolisation;
 Special Focus: Haemorrhage;

Figure 6 Abdominal CE-CT - 1 week after the embolisation



Both haematomas have reduced in size and contrast extravasation is no longer present. In the right kidney a peripheral postero-lateral cortical wedge-shaped non-enhancing area corresponding to the post-embolisation infarct can be observed.

Area of Interest: Kidney;
Imaging Technique: Ultrasound;
Procedure: Diagnostic procedure;
Special Focus: Haemorrhage;

MeSH

Kidney [A05.810.453]

Body organ that filters blood for the secretion of URINE and that regulates ion concentrations.

Biopsy [E01.370.388.100]

Removal and pathologic examination of specimens in the form of small pieces of tissue from the living body.

References

- [1] Lefaucheur C, Nochy D, Bariety J (2009) Renal biopsy: procedures, contraindications, complications *Néphrologie & Thérapeutique* 5:331-9
- [2] Uppot RN, Harisinghani MG, Gervais DA (2010) Imaging-Guided Percutaneous Renal Biopsy: Rationale and Approach *American Journal of Radiology* 194:1443-1449
- [3] Sinha MD, Lewis MA, Bradbury MG, Webb NJ (2006) Percutaneous renal real-time ultrasound-guided biopsy by automated biopsy gun in children: safety and complications *Journal of Nephrology* 19:41-4
- [4] Atwell TD, Smith RL, Hesley GK, Callstrom MR, Schleck CD, Harmsen WS, Charboneau JW, Welch TJ (2010) Incidence of bleeding after 15,181 percutaneous biopsies and the role of aspirin *AJR American Journal of Roentgenology* 194:784-9
- [5] Sadick M, Röhl B, Schnülle P, Düber C, Diehl SJ (2007) Multislice CT-angiography in percutaneous postinterventional hematuria and kidney bleeding: Influence of diagnostic outcome on therapeutic patient management. Preliminary results *Archives of Medical Research* 38:126-32
- [6] Jain V, Ganpule A, Vyas J, Muthu V, Sabnis RB, Rajapurkar MM, Desai MR (2009) Management of non-neoplastic renal hemorrhage by transarterial embolization *Urology* 74:522-6
- [7] Mavili E, Dönmez H, Ozcan N, Sipahiolu M, Demirta A. (2009) Transarterial embolization for renal arterial bleeding *Diagnostic and Interventional Radiology* 15:143-7
- [8] Schwartz MJ, Smith EB, Trost DW, Vaughan ED Jr (2006) Renal artery embolization: clinical indications and experience from over 100 cases *BJU International* 99:881-6
- [9] Toledo K, Pérez MJ, Espinosa M, Gómez J, López M, Redondo D, Ortega R, Aljama P (2010) Complications associated with percutaneous renal biopsy in Spain, 50 years later *Nefrologia* 30:539-43
- [10] Janik V, Martinek V, Padr R, Lisy J, Neuwirth J, Pafcugova J, et al (2005) Embolization of

lumbar artery due to retroperitoneal bleeding following renal biopsy Nephrology Dialysis Transplantation 20:820-2

[11] Wall B, Keller FS, Spalding DM, Reif MC (1986) Massive hemorrhage from a lumbar artery following percutaneous renal biopsy American Journal of Kidney Diseases 7:250-3

[12] Kim KT, Kim BS, Park YH, Cho KJ, Shinn KS, Bahk YW (1991) Embolic control of lumbar artery hemorrhage complicating percutaneous renal biopsy with a 3-F coaxial catheter system: case report Cardiovascular and Interventional Radiology 14:175-8

Citation

Cabral P¹, Donato P², Caseiro-Alves F²

(1) Department of Radiology of Hospital Prof. Dr. Fernando Fonseca, Amadora, Portugal

(2) Department of Radiology of Hospital Universidade Coimbra, Coimbra, Portugal (2011, Nov. 4)

Renal biopsy complication and treatment {Online}

URL: <http://www.eurorad.org/case.php?id=9614>