

## Correspondence

European Journal of Anaesthesiology 2009, 26:611–624

### Low bispectral index values in hydranencephaly

Antonio Pérez-Ferrer<sup>a</sup>, Elena Gredilla<sup>a</sup>, Jesús de Vicente<sup>a</sup>, Yolanda Laporta<sup>a</sup> and Catarina Madeira<sup>b</sup>

<sup>a</sup>Department of Paediatric Anaesthesiology, La Paz University Hospital, Madrid, Spain and <sup>b</sup>Anaesthesia Resident, Fernando Fonseca Hospital, Lisbon, Portugal

Correspondence to Antonio Pérez-Ferrer, Department of Paediatric Anaesthesiology, La Paz University Hospital, Paseo de la Castellana 261, 28046 Madrid, Spain

Tel: +34917277288; e-mail: antonioperezferrer@gmail.com

Received 18 July 2008 Revised 13 August 2008

Accepted 14 August 2008

Editor,

We read with great interest the article by Prabhakar *et al.* [1] regarding the use of bispectral index (BIS) monitoring for an elective frontal craniotomy and fenestration in a 2-year-old boy with bilateral frontal lobe porencephalic cysts. During the procedure, the patient presented low preanaesthetic BIS values (39) that showed no significant change (between 30 and 40), despite a reduction in the inspired concentration of sevoflurane from 1 to 0.2%. No burst suppression pattern was observed, and BIS values remained low after anaesthetic recovery. In the discussion, the authors suggest that intracranial pressure increments could be responsible for the low BIS values.

We believe that we present the first case of BIS monitoring in hydranencephaly, an extreme form of porencephaly. With it we hope to throw light on the origin of low BIS values recorded in these patients.

A 5-month-old boy, weighing 4.5 kg, with the diagnosis of hydrocephalus, was scheduled for endoscopic ventriculostomy and coagulation of choroid plexus.

Hydranencephaly is a rare condition in which the brain's cerebral hemispheres are absent and replaced by sacs filled with cerebrospinal fluid. It is characterized by near total or total absence of cerebral cortex and basal ganglia. The thalami, pons, cerebral peduncles, and cerebellum are usually present, as may be a small amount of tissue from the occipital, frontal, and temporal lobes. At birth, children with hydranencephaly may appear normal, spontaneous reflexes such as sucking, swallowing, crying, and moving the arms and legs may all seem normal, but developmental delay becomes apparent within a few weeks. Common manifestations of this condition include irritability, abnormal muscle tone, seizures, and increased head size (as a result of hydrocephalus). Swallowing difficulties lead to malnutrition, aspiration, and pneumonia.

Our patient presented global hypotonia but had developed social smile, was able to hold up his head, managed to focus and track an object with both eyes and reacted to sounds.

MRI revealed bilateral multiple porencephalic cysts replacing the cerebral hemispheres (Fig. 1). Electroencephalogram (EEG) showed a slow activity pattern with low amplitude waves compatible with severe damage to cerebral electrogenesis.

Anaesthesia was induced with an increasing sevoflurane/oxygen mixture (1–3–6%) delivered by facemask, with atropine, fentanyl (10 µg) and atracurium. Tracheal intubation was performed using a 4-mm uncuffed Portex single lumen tube.

General anaesthesia was maintained using an oxygen mixture with sevoflurane (2%). In order to monitor anaesthetic depth, brain electrical activity was continuously measured with an A 2000-XP BIS Monitor (Aspect Medical Systems, Newton, Massachusetts, USA). Paediatric low-impedance electrodes were attached to the patient's frontal area as specified by the manufacturer.

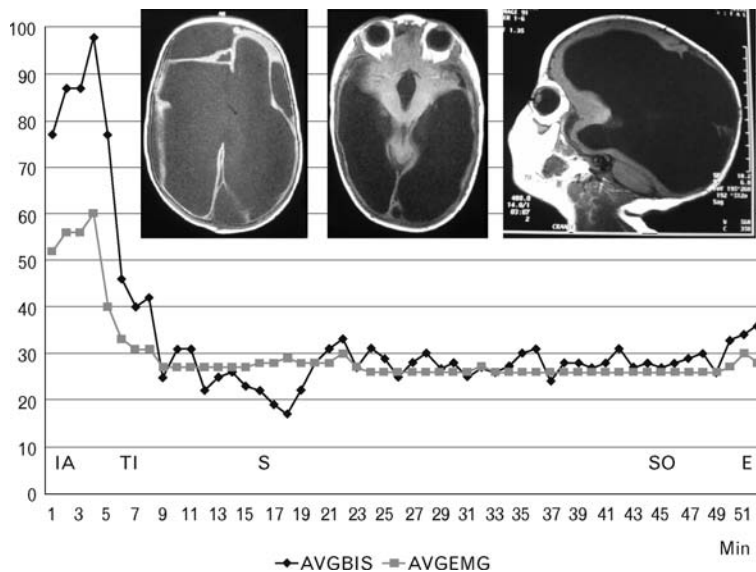
Initial average BIS values (AVGBIS) were above 80, probably due to a low signal-quality index (SQI); however, during anaesthetic maintenance recorded values were persistently below 30, with a SQI higher than 90%. Interestingly, average electromyography values (AVGEMG) were practically the same as AVGBIS (Fig. 1).

BIS records cortical electroencephalographic signals. However, in the absence of EEG signals or in extreme EEG suppression situations (as occurs in brain death or patients with deep hypothermia) the BIS algorithm becomes very vulnerable to a wide range of artefacts [2]. As a consequence, the ECG or high electromyographic signals [3] can be misinterpreted as EEG activity [4].

The EMG frequencies overlap the BIS algorithm's beta ratio in the 30–47 Hz range, associated with awake or light levels of anaesthesia. Thus, EMG values within this range can be misinterpreted by the BIS algorithm as EEG activity and a spuriously increased BIS value can be recorded.

The BIS variable was created following collection of clinical data from healthy volunteers with normal EEG. It is therefore not surprising that neurological disorders that manifest abnormal EEG patterns can affect

Fig. 1



MRI showing bilateral multiple porencephalic cysts replacing the brain's cerebral hemispheres. Average bispectral index values and average electromyography values during surgery. E, extubation; IA, induction of anesthesia; S, surgery; SO, time of turning off the sevoflurane vaporizer; TI, tracheal intubation.

BIS monitoring. It has been described that patients with Alzheimer's type dementia and children with West syndrome and lissencephaly show low preanaesthetic BIS values. In the same way, children with cerebral palsy present lower values during and after anaesthesia than healthy ones. In porencephaly, the EEG recorded over porencephalic cysts is characterized by increased theta and delta bands in the areas surrounding the injury identified by computed tomography [5]. Taking into account that the BIS algorithm is based on electroencephalogram processing, it is not unexpected that low BIS values were recorded in this disease.

In this case, due to the cysts, the cerebral cortex and consequently the cerebral electrogenesis are diminished in such a manner that EMG activity might be the main component of the BIS value. If we analyse the variance of AVGBIS and AVGEMG values recorded during surgery, the AVGEMG value might explain a significant amount of AVGBIS variability ( $F$  Snedecor = 529637;  $df = 1$ ;  $P < 0001$ ). The corrected determination coefficient ( $r^2$  corrected) indicates that the AVGEMG value explains 91.2% of AVGBIS variation.

Intracranial pressure (ICP) increase caused by the cysts can provoke a reduction in cerebral perfusion pressure and global cerebral ischaemia. This fact would also explain the marked decrease in BIS values. However, in our opinion, this was not the main physiopathological mechanism of BIS reduction, neither in our case report nor in the one reported by Prabhakar *et al.* [1]. This reduction cannot be explained by increased ICP because

it was not measured, and there was no clinical evidence of a sufficient rise in ICP that could explain a significant decrease in cerebral perfusion pressure. Furthermore, there was no record of an increase of burst suppression paralleling a BIS decrease in any of the cases, as we could expect in this situation [6]. It seems more reasonable that low BIS values were explained by cerebral cortex loss.

There is evidence that placement of BIS monitor leads in positions different from those advised by the manufacturer may still provide interpretable readings. A statistically significant correlation of BIS values between frontal and occipital placement of electrode strips has been demonstrated [7]. In dolphins, it has been proven that a BIS monitor can detect interhemispheric asymmetry in electroencephalographic activity during sleep. For this reason, it is possible that the position of the electrodes might make a difference in cases of neurological injury, such as the case reported by Prabhakar *et al.* [1]. In this case, most of the cerebral mass was located in the occipital area; therefore, placement of BIS monitor leads in this zone could have increased the amount of data obtained.

Cerebral function monitoring is a new application of BIS, which is different from its initial purpose. Although BIS is a well accepted monitor for anaesthetic depth, several factors, unrelated to anaesthesia, can modify it. Several clinical observations suggest that BIS monitoring can be used as an 'alarm signal' to detect repercussions of hypoxic, ischaemic or other similar injuries on cerebral function as long as the depth of anaesthesia is controlled.

However, further studies are needed to validate the use of BIS for this purpose and address its potential applications and limitations.

In contrast, patients with neurological disorders who manifest abnormal EEG patterns will probably have significant changes in BIS monitoring readings. Accordingly, in these patients one has to be careful in interpreting BIS values because, as in the hydranencephaly case, recordings correspond more to EMG activity than to the EEG of cerebral cortex.

## References

- 1 Prabhakar H, Ali Z, Bithal PK, *et al.* Low bispectral index values in a 2-yr-old with a large bifrontal proencephalic cyst. *Eur J Anaesthesiol* 2008; **25**:513–514.
- 2 Dahaba AA. Different conditions that could result in the bispectral index indicating an incorrect hypnotic state. *Anesth Analg* 2005; **101**:765–773.
- 3 Myles PS, Cairo S. Artifact in the bispectral index in a patient with severe ischemic brain injury. *Anesth Analg* 2004; **98**:706–707.
- 4 Vivien B, Paqueron X, Le Cosquer P, *et al.* Detection of brain death onset using the bispectral index in severely comatose patients. *Intensive Care Med* 2002; **28**:419–425.
- 5 Cerquiglini A, Seri S, Sturmiolo MG, *et al.* Computerized electroencephalographic assessment of congenital brain infarction. *Childs Nerv Syst* 1994; **10**:252–258.
- 6 Morimoto Y, Monden Y, Ohtake K, *et al.* The detection of cerebral hypoperfusion with bispectral index monitoring during general anesthesia. *Anesth Analg* 2005; **100**:158–161.
- 7 Shiraishi T, Uchino H, Sagara T, *et al.* A comparison of frontal and occipital bispectral index values obtained during neurosurgical procedures. *Anesth Analg* 2004; **98**:1773–1775.

DOI:10.1097/EJA.0b013e32831bd8e7

## Does topical application of adrenaline on nasal mucosa induce significant haemodynamic changes under general anaesthesia?

Xiaokui Li<sup>a,1</sup>, Tianzuo Li<sup>a,1</sup>, Demin Han<sup>b</sup>, Xiaohong Song<sup>a</sup> and Luo Zhang<sup>b</sup>

<sup>a</sup>Department of Anaesthesiology and <sup>b</sup>Department of Otolaryngology-Head and Neck Surgery, Beijing Tongren Hospital, Capital Medical University, Beijing, P.R. China

Correspondence to Luo Zhang, Department of Otolaryngology-Head and Neck Surgery, Beijing Tongren Hospital, Capital Medical University, Beijing, P.R. China

Received 7 August 2008 Revised 9 October 2008

Accepted 10 October 2008

Editor,

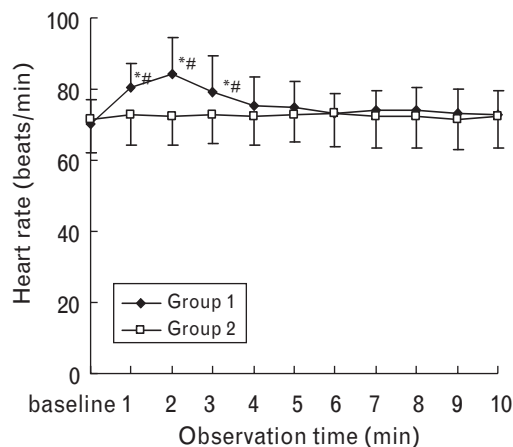
Nasal application of adrenaline-containing local anaesthetic is widely used in endoscopic sinus surgery (ESS). However, some recent clinical observations have shown that, in healthy adults, nasal infiltration with 2% lidocaine or physiological saline with adrenaline (1 : 200 000) caused a significant mean arterial pressure (MAP) decrease, which indicates that a low dose of adrenaline is related to marked hypotension [1–4].

<sup>1</sup> Dr Xiaokui Li and Dr Tianzuo Li contributed equally to the writing of this article.

The present study is a prospective, randomized and double-blinded clinical study. The study was approved by the Institute Ethics Committee of Beijing Institute of Otolaryngology and conducted according to the Helsinki Declaration. The observation was from January to August 2006. Written informed consent was obtained from all the patients. All patients were ASA physical status I or II without a history of coronary artery disease, hypertension, arrhythmia, diabetes or previous ESS. Group I received 1% tetracaine with 1 : 10 000 adrenaline for nasal anaesthesia; group II received 1% tetracaine only. An appointed nurse prepared the different solutions; neither the surgeons nor the anaesthetists, including the observer, knew which solution was used. Without premedication, anaesthesia was induced with midazolam 0.03 mg kg<sup>-1</sup>, remifentanyl 1.5 µg kg<sup>-1</sup> and propofol 2 mg kg<sup>-1</sup>. Atracurium 0.5 mg kg<sup>-1</sup> was used to facilitate orotracheal intubation with a cuffed tube. Anaesthesia was maintained with 1% isoflurane, nitrous oxide 60% in oxygen. The patients were mechanically ventilated to maintain the end tidal carbon dioxide tension at around 35–40 mmHg. Plasma expanders (hetastarch 3–6 ml kg<sup>-1</sup>) and crystalloid (Ringer's lactate 3–6 ml kg<sup>-1</sup>) were infused to prevent MAP and heart rate (HR) fluctuation before nasal packing. Ten minutes after the induction of general anaesthesia and endotracheal intubation, two tetracaine (with or without adrenaline)-soaked cotton plugs were inserted into each nasal cavity (common meatus and middle meatus) and removed 5 min later. The amount of tetracaine solution absorbed by one plug was about 2 ml. A radial artery cannula was inserted before the induction of anaesthesia and blood pressure could be monitored directly and continuously. Systolic blood pressure (SBP), MAP, diastolic blood pressure (DBP) and HR were recorded continuously at the following 11 time points: before tamponade (baseline) and every minute after tamponade until the 10th minute.

Thirty adult patients, including 19 men and 11 women, were recruited, with 15 patients in each group. The mean age was 38 years with a range of 18–50 years. There was no significant difference between the two groups of patients with regard to age, sex, body weight, and volume of intravenous fluid infusion, baseline of BP and baseline of HR. In group I and group II, at all the observation time points after tamponade, SBP, DBP and MAP showed no significant changes compared with baseline. Whereas HR in group II showed no significant changes compared with baseline ( $P > 0.05$ ), HR in group I showed a transient increase, starting from 1 min ( $80.3 \pm 6.8$  beats min<sup>-1</sup>,  $P < 0.05$ ). It reached a peak ( $84.2 \pm 10.1$  beats min<sup>-1</sup>,  $P < 0.05$ ) during the next minute and then decreased by the 3 min point ( $79.3 \pm 10.2$  beats min<sup>-1</sup>,  $P < 0.05$ ). Moreover, at these three time points, HR was also higher than that in group II ( $P < 0.05$ ). From the 4th minute to the end of the observation, HR slowed down towards the baseline level and showed no differences from that in group I at the same time point (Fig. 1).

Fig. 1



Heart rate (HR) in group 1 showed significant increase at 1, 2 and 3 min after topical anaesthesia compared with baseline, also higher than those values in group II at the same observation time. \* $P < 0.05$ , versus intragroup baseline data. # $P < 0.05$ , versus group II.

Topical application of local anaesthetics with adrenaline is widely used to relieve pain, decrease surgical bleeding and allow better visualization of the surgical field in ESS. It has been generally accepted that no severe cardiovascular event is related to this procedure [5,6]. However, some studies [1–4] revealed different haemodynamic changes after local infiltration of adrenaline. The controversy was based on different local anaesthesia techniques and adrenaline concentrations (for example 1:1000 for topical [5], 1:80 000 [7], 1:100 000 [5], 1:200 000 [1,2] and 1:400 000 [3] for infiltration).

According to our findings, in healthy adults undergoing ESS under general anaesthesia, no significant blood pressure changes were detected after nasal packing with 1% tetracaine-soaked (with or without 1:10 000 adrenaline) plugs.

The HR changes in different studies are also controversial. We found nasal packing with 1:10 000 adrenaline-soaked plugs caused a transient and significant increase in HR, and restored quickly within 4 min, which is consistent with the findings of John *et al.* [8], although they used infiltration with 1:80 000 adrenaline. The increase in HR might be mainly the result of baroreceptor reflex and some stimulation of  $\beta_1$ -receptors [1,2].

Effects of adrenaline on arterial pressure and HR are dose dependent. As a direct acting  $\alpha$ -receptor and  $\beta$ -receptor agonist produced by the adrenal medulla, adrenaline may activate different types of sympathetic receptors at different doses. A dose of less than  $2 \mu\text{g}$  should predominantly activate  $\beta_2$ -receptors, resulting in vascular relaxation; a dose of 2–10  $\mu\text{g}$  should predominantly activate  $\beta_1$ -receptors to increase HR, contractility and conduction

and decrease the refractory period. Doses in excess of 10  $\mu\text{g}$  cause marked  $\alpha$ -stimulation with resultant generalized vasoconstriction. Thus, the plasma concentration of adrenaline should have a close relationship with activation of sympathetic receptors.

Systemic absorption of adrenaline may occur when local infiltration or topical tamponade or both are applied. Systemic effects of adrenaline are variable in different patients and are related to the blood concentrations. Various studies have shown that the haemodynamic changes after local infiltration of adrenaline also depend on the physical status of the patient, vascularity of the site of administration and the rate of absorption from the area infiltrated [1]. Also, the plasma concentration of adrenaline might be affected by other factors such as the anaesthesia method and the depth of general anaesthesia.

In addition, the plasma concentration of adrenaline is made up of endogenous adrenaline and exogenous adrenaline. Pain or surgery may produce much more endogenous adrenaline than the exogenous amount of adrenaline absorbed from the local applications. This could explain why, in spite of several studies having been carried out, no defined correlations between the amount of local application and plasma concentration of adrenaline has been established. Therefore, the haemodynamic changes are not merely the result of a low dose of adrenaline as a local vasoconstrictor.

Local anaesthetic technique might be another explanation why we detected only increased HR, but not marked hypotension. Local infiltration or topical application might influence the amount of adrenaline absorbed; the procedure *per se* causes different pain impulses and accordingly the plasma concentration of adrenaline could be different. Therefore, hypotension, hypertension or HR increase might be the result. Our study showed that topical use of tetracaine and adrenaline did not cause blood pressure changes under general anaesthesia, which at least suggests that nasal tamponade might be better than local infiltration in ESS as there are adverse effects.

Deep anaesthesia may be a prerequisite for the adrenaline-induced hypotension [1]. Li *et al.* [4] reported recently that relatively light anaesthesia can reduce the severity of adrenaline-induced hypotension during ESS. And accordingly, the increase in HR was significantly lower. In our study, the inhaled concentration of isoflurane was only 1%, which also represented a relatively light general anaesthesia and no severe hypotension was seen either.

As most clinical observations, including ours, did not measure the plasma concentration, we can only compare changes in BP and HR. The reason might be that the different plasma concentrations of adrenaline resulted in

the activation of different sympathetic receptors; ultimately, a faster HR with or without hypotension could be observed.

## References

- 1 Yang JJ, Li WY, Ji LQ, *et al.* Local anaesthesia for functional endoscopic sinus surgery employing small volumes of adrenaline-containing solutions of lidocaine produces profound hypotension. *Acta Anaesthesiol Scand* 2005; **49**:1471–1476.
- 2 Yang JJ, Wang QP, Wang TY, *et al.* Marked hypotension induced by adrenaline contained in local anaesthetic. *Laryngoscope* 2005; **115**:348–352.
- 3 Zhao F, Wang Z, Yang J, *et al.* Low-dosage adrenaline induces transient marked decrease of blood pressure during functional endoscopic sinus surgery. *Am J Rhinol* 2006; **20**:182–185.
- 4 Li W, Zhou Z, Ji J, *et al.* Relatively light general anaesthesia is more effective than fluid expansion in reducing the severity of adrenaline-induced hypotension during functional endoscopic sinus surgery. *Chin Med J* 2007; **120**:1299–1302.
- 5 Anderhuber W, Walch C, Nemeth E, *et al.* Plasma adrenaline concentrations during functional endoscopic sinus surgery. *Laryngoscope* 1999; **109**:204–207.
- 6 Riegle EV, Gunter JB, Lusk RP, *et al.* Comparison of vasoconstrictors for functional endoscopic sinus surgery in children. *Laryngoscope* 1992; **102**:820–823.
- 7 Kara CO, Kaftan A, Atalay H, *et al.* Cardiovascular safety of cocaine anaesthesia in the presence of adrenaline during septal surgery. *Otolaryngology* 2001; **30**:145–148.
- 8 John G, Low JM, Tan PE, *et al.* Plasma catecholamine levels during functional endoscopic sinus surgery. *Clin Otolaryngol* 1995; **20**:213–215.

DOI:10.1097/EJA.0b013e32831de4fc

## Discomfort following transurethral cystoscopy and catheterization: effects of gender and topical steroids

Ahmed A. Shorrab<sup>a</sup>, Hassan Abol-Enein<sup>b</sup>, Amir Shabana<sup>a</sup>, Samir Elhanbly<sup>c</sup> and Hisham Abdel-Mohaymen<sup>a</sup>

<sup>a</sup>Departments of Anesthesia, <sup>b</sup>Urology and <sup>c</sup>Andorology, Faculty of Medicine, University of Mansoura, Egypt

Correspondence to Ahmed A. Shorrab, MD, Assistant Professor of Anesthesia, Department of Anesthesia, Mansoura Faculty of Medicine, Mansoura, Egypt  
Tel: +20 50 2268310; fax: +20 50 223 2700; e-mail: shorrab@mans.edu.eg

Received 27 August 2008 Revised 28 September 2008  
Accepted 17 October 2008

Editor,

Following cystoscopic procedures and urethral catheterization, patients usually have a degree of urethral discomfort ranging from a burning sensation with the desire to micturate to severe agony and distress about the indwelling catheter. Discomfort can be extremely disabling on arrival in the recovery room and can cause the nurse to spend an inordinate amount of time with these patients. This discomfort can be explained by bladder-induced irritation [1] with manifestations of overactive bladder. It has been reported to be relieved with pre-treatment with oral antimuscarinic drugs [1] or intravenous analgesics with subsidiary antimuscarinic properties such as ketamine [2]. We hypothesized that transurethral endoscopy or catheterization or both shear the urethral mucosa and induce a degree of inflammation, leading to

varying degrees of discomfort. We believe that application of topical steroid may allay the urethral discomfort through its soothing and anti-inflammatory effects. This was tested in a controlled randomized observer-blinded study in patients undergoing urethral catheterization following transurethral endoscopic procedures under general anaesthesia. The outcome measures were recovery parameters and the degree of urethral discomfort.

After obtaining approval of the local ethics committee and consent of the patients, adult patients undergoing elective transurethral endoscopic procedures for suspected bladder disease were enrolled into the study. A pilot study was initially conducted to observe manifestations of discomfort in 85 patients, including 56 men and 29 women, undergoing transurethral endoscopy and catheterization. Moderate-to-severe discomfort was encountered in 26 men (46%) and four women (14%). These results demonstrate that urethral discomfort following transurethral endoscopy and catheterization is mainly a male complaint. Consequently, female patients were excluded from the study.

Patients were premedicated with oral diazepam (10 mg) 2 h before the procedure. Anaesthesia was induced with intravenous injection of fentanyl (1.5 µg kg<sup>-1</sup>) followed by propofol (2.0 mg kg<sup>-1</sup>) to facilitate insertion of the laryngeal mask airway. Anaesthesia was maintained during spontaneous breathing with isoflurane in a mixture of oxygen and nitrous oxide, with an FiO<sub>2</sub> of 0.4.

A computer-generated randomization table was used to randomly allocate adult male patients to either the control group without application of topical cream or the study group with topical steroid cream applied to the whole urethra at the end of the procedure. The steroid cream, Dermatop (Aventis Pharma, Global Napi Pharmaceuticals, Cairo, Egypt) (5 g = 12.5 mg prednicarbate), was applied by the endoscopist with a special applicator. The endoscopist ensured distribution of the cream to the whole length of the urethra and clamped the glans for 2 min before insertion of the urethral catheter. In both groups, a Foley's catheter of size 18 Fr lubricated with KY jelly was used and fixed without traction. Its balloon was inflated with 20 ml of water. An observer, blinded to patient group assignment and unaware of the treatment, was present at the end of the anaesthesia and escorted the patient to the recovery room. Emergence was recorded in the form of behavioural responses such as flailing limbs, strong vocal response or attempts to pull the catheter out. The degree of discomfort was assessed according to Agarwal *et al.* [2] as: first, no discomfort when the patient is comfortable and not reporting any discomfort even after nonleading interrogation; second, mild discomfort with the patient comfortable but complaining about the catheter after nonleading interrogation; third, moderate discomfort when the patient reported discomfort from

the catheter without questioning but this was not accompanied by behavioural responses; and, fourth, severe discomfort reported by the patient accompanied by behavioural responses. Rescue treatment was initiated in patients with moderate-to-severe discomfort with ketorolac (30 mg intravenous) then fentanyl (50 µg intravenous) bolus 10 min later when deemed necessary. Discharge criteria from the recovery room were stable vital signs and absence of urethral discomfort in a fully conscious patient, the study end point.

On the basis of the pilot study, we assumed that the application of topical steroid cream to the urethra would decrease the incidence of discomfort from 46 to 20%. A total of 42 patients in each group were needed to provide a power of 0.8 with  $\alpha$  error 0.05 and  $\beta$  error 0.2. Statistical analysis was carried out using SPSS version 10.0 (SPSS Inc., Chicago, Illinois, USA). Parametric data were analysed by Student's *t*-test, whereas nonparametric variables were analysed using the Fisher's exact test. A *P* value of less than 0.05 was considered significant.

Two patients were excluded from the control group: one patient underwent meatotomy and dilatation and the other patient had bladder perforation that was discovered in the recovery room. Two patients were excluded from the study group: one patient underwent internal urethrotomy for stricture urethra and the second patient underwent bladder neck incision. Forty patients in each group were subjected to statistical analysis. Patients in the steroid group had a better quality of emergence, less discomfort, fewer analgesic requirements and shorter recovery room stay than the control group (Table 1). The incidence of discomfort in the control and steroid groups was 60 and 15%, respectively, with a relative risk reduction of 0.75, absolute risk reduction of 0.45 and a number needed to treat of 2.3, that is, two to three patients need to be treated with topical steroids in order to prevent one patient from having discomfort.

**Table 1 Patients' characteristics and results of the study**

	Control (n = 40)	Steroid (n = 40)
Age (years)	53 ± 10.7	50 ± 9.4
Body weight (kg)	70 ± 11.3	69 ± 13
Duration of procedure (min)	42 ± 14.7	41 ± 12.9
Duration of recovery room stay (min)	70 ± 18	40 ± 14*
Emergence		
Calm	26	34
Restless	6	5
Thrashing	8	1*
Discomfort		
No discomfort	16	34*
Discomfort	24	6*
Degree of discomfort		
Mild	6	3
Moderate	8	2*
Severe	10	1*
Number of patients needed analgesics	18	3*
Ketorolac	8	2
Ketorolac and fentanyl	10	1

Data are means ± SD or number of patients. \*Significant; *P* < 0.05.

The female urethra (4 cm) is shorter than the male urethra (20 cm). The female urethra, 6 mm in diameter, is much more readily dilatable than the male urethra because it is rich in elastic and collagen fibres [3]. These anatomical differences between the male and female urethra may explain the high incidence of discomfort in men undergoing transurethral manoeuvres.

Gabapentin was used in the treatment of catheter-related discomfort [4]. Gabapentin was able to ameliorate this discomfort probably because of its peripheral anti-inflammatory effects [5]. These effects may partially support our hypothesis about the urethral origin of catheter-related discomfort. From the embryological and anatomical standpoint, the urethral plate is a continuation of the trigone of the urinary bladder [3]. Therefore, urethral irritation may induce bladder irritation through trigonal stimulation. Transurethral manoeuvres may lead to discomfort through many mechanisms, namely, sheared mucosa and foreign body irritation. In the present study, urethral application of prednicarbate relieved discomfort and improved patient recovery. Prednicarbate is a non-halogenated prednisolone double ester with potent anti-inflammatory effects that inhibits interleukin (IL)-1 and IL-6 [6]. The application of topical steroids was successfully used to reduce sore throat, cough and hoarseness after tracheal intubation [7]. These effects on the tracheal mucosa may, in some ways, mimic the effects of catheter-induced urethral irritation.

In conclusion, discomfort following cystoscopy and catheterization is mainly a male complaint. Topical steroid cream (prednicarbate) applied to the urethra for 2 min can effectively reduce this discomfort and improve the quality of emergence from anaesthesia.

## References

- Agarwal A, Raza M, Singhal V, *et al*. The efficacy of tolterodine for prevention of catheter related bladder discomfort: a prospective, randomized, placebo controlled, double-blind study. *Anesth Analg* 2005; **101**:1065–1067.
- Agarwal A, Gupta D, Kumar M, *et al*. Ketamine for treatment of catheter related bladder discomfort: a prospective, randomized, placebo controlled and double-blind study. *Br J Anaesth* 2006; **96**:587–589.
- Jordan GH, Schlossberg SM. Surgery of the penis and urethra. In: Kavoussi LR, Novick AC, Partin AW, editors. *Campbell-Walsh urology*, 9th ed. Philadelphia: Saunders, Elsevier; 2007. pp. 1023–1097.
- Agarwal A, Dhiraaj S, Sandeep P, *et al*. An evaluation of the efficacy of gabapentin for prevention of catheter-related bladder discomfort: a prospective, randomized, placebo-controlled, double-blind study. *Anesth Analg* 2007; **105**:1454–1457.
- Stanfa LC, Singh L, Williams RG, Dickenson AH. Gabapentin, ineffective in normal rat, markedly reduces C-fibre evoked responses after inflammation. *Neuroreport* 1997; **8**:578–590.
- Lange K, Kleuser B, Gysler A, *et al*. Cutaneous inflammation and proliferation in vitro: differential effects and mode of action of topical glucocorticoids. *Skin Pharmacol Appl Skin Physiol* 2000; **13**:93–103.
- Ayoub CM, Ghobashy A, Koch ME, *et al*. Widespread application of topical steroids to decrease sore throat, hoarseness, and cough after tracheal intubation. *Anesth Analg* 1998; **87**:714–716.

DOI:10.1097/EJA.0b013e32831f3475

## Enoxaparin induced intracerebral haemorrhage after deep brain stimulation surgery

Zulfiqar Ali, Hemanshu Prabhakar, Girija P. Rath and Hari H. Dash

Department of Neuroanaesthesiology, All India Institute of Medical Sciences, New Delhi, India

Correspondence to Dr Hemanshu Prabhakar, MD, Assistant Professor, Department of Neuroanaesthesiology, Neurosciences Center, All India Institute of Medical Sciences, New Delhi 110029, India  
 Fax: +91 11 26862663;  
 e-mail: prabhakarhemanshu@rediffmail.com

Received 30 October 2008 Accepted 4 November 2008

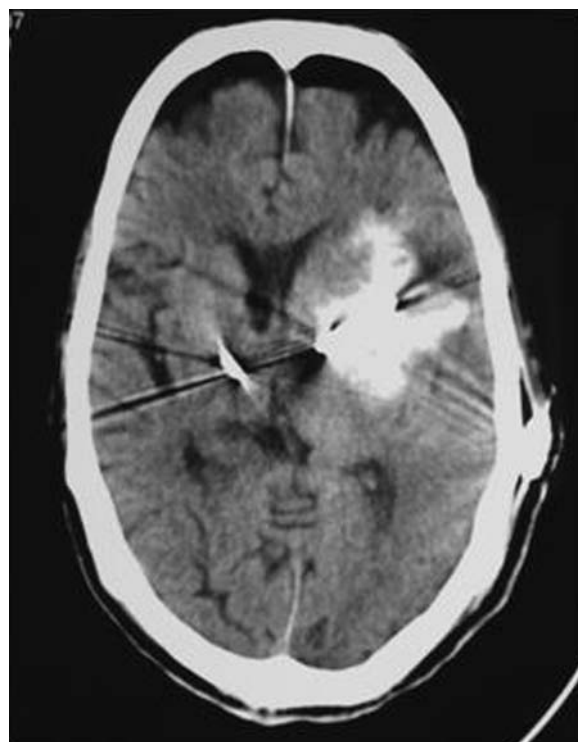
Editor,

Critically ill neurological patients are prone to deep vein thrombosis (DVT), as they remain bedridden for prolonged periods. Thromboprophylaxis is of paramount importance for prevention of this complication. Use of low molecular weight heparin (enoxaparin) has been recommended for prevention of deep venous thrombosis. The risk of haemorrhage with enoxaparin into the operation site in neurosurgical patients can be more dangerous than with other surgeries. Enoxaparin, a low molecular weight heparin, acts by inhibiting coagulation factors such as Xa and IIa and by activating the antithrombin III. Factor Xa catalyzes the conversion of prothrombin to thrombin. Inhibition of this process by enoxaparin results in decreased thrombin and prevention of fibrin clot formation. Intracerebral bleeding has been previously reported as a perioperative complication following deep brain stimulation (DBS) surgery [1]. We report a case of anticoagulant (enoxaparin) induced intracerebral haemorrhage in an elderly patient who underwent surgery for DBS in the postoperative period. A search in literature did not reveal any similar result.

A 75-year-old male was admitted with history of tremulousness of right upper limb and both lower limbs associated with sluggishness of movements, decreased volume and slurring of speech for 3 years. Over a period of 6 months, symptoms progressed to such an extent that he had a fall while walking and fractured his acetabulum. Examination revealed hypertonia, bradykinesia, rigidity and postural instability. A diagnosis of Parkinson's disease was made. He was prescribed syndopa (levodopa 100 mg + carbidopa 10 mg). After initial response, drugs had to be increased because of waning effects. There was no improvement in symptoms inspite of addition of ropinirole, entacapone and selegiline. Hence, DBS was planned. He had a past history of hypertension and coronary artery disease for which a coronary artery bypass graft surgery had been done 10 years back. There was also history of retinal detachment and subdural hematoma 12 years

back. The DBS procedure was carried out in two stages. In the first stage, the microelectrodes were placed in the subthalamic nucleus bilaterally under monitored anaesthesia care. This was followed by placement of stimulator with battery in the anterior chest wall under general anaesthesia and mechanical ventilation. The trachea was extubated at the end of the procedure and patient shifted to neurosurgical ICU. On the fifth postoperative day, enoxaparin (40 mg) was administered for prophylaxis of DVT. Within a few hours of receiving the first dose of enoxaparin, the patient became unresponsive. The trachea was reintubated and the patient taken for computed tomography (CT) scan. Intracerebral haemotoma in the left basal ganglia and left fronto-parietal region with midline shift and perilesional oedema was seen on the CT scan (Fig. 1). Prothrombin time ( $24\text{ s}$  control  $12\text{ s}^{-1}$ ) and activated partial thromboplastin time ( $33\text{ s}$  control  $30\text{ s}^{-1}$ ) were prolonged with a normal platelet count. Enoxaparin was discontinued, and six units of fresh frozen plasma were transfused. Mechanical ventilation was continued. Patient's coagulation status returned to normal within the next 4 days, and there was an improvement in the neurological status. As the haematoma had resolved and was not expanding, the surgeons

Fig. 1



A computed tomographic scan showing intracerebral hemotoma in left basal ganglia and left fronto-parietal region with midline shift and perilesional edema.

decided against its evacuation. However, soon the patient developed ventilator-associated pneumonia and sepsis due to methicillin-resistant *Staphylococcus aureus* to which he succumbed on the twenty-fifth day of his ICU stay.

DBS is being increasingly practiced in elderly patients for tremor-dominant disorders, Parkinson's disease and dystonias. Although DBS is supposed to be as effective in elderly patients as in younger ones, systematic studies on the complication rate, the effectiveness and, therefore, the risk-benefit ratio of DBS in elderly patients are still lacking. Elderly population has a higher incidence of coexisting medical disorders. DBS should be considered in patients with early stages of disease, as the incidence of general complications increases with age, whereas natural life expectancy decreases. DBS is a minimally invasive neurosurgical procedure with reported perioperative surgical complications such as haemorrhage, seizure, confusion [2], venous air embolism [3] and tension pneumocephalus [4]. In the postoperative period pneumonia, skin infections [5] and transient psychoses are frequent complications.

Our patient developed an intracranial haematoma, possibly due to prophylactic anticoagulation. His neurological condition worsened when a low molecular weight heparin was given 5 days after the original surgery. There were no apparent aggravating factors such as clotting derangements or sepsis. Although the aim was to prevent DVT, this case illustrates the possible hazard of enoxaparin administration.

Though there are no specific guidelines on the use of enoxaparin in traumatic brain injury, some studies do not support routine prophylaxis [6], whereas others recommend safe use of enoxaparin for DVT prophylaxis within 24 h after hospital admission or after craniotomy [7]. In elective neurosurgical patients, it has been seen that there is an increase in the postoperative intracranial haemorrhage when enoxaparin was initiated preoperatively in patients with brain tumours [8]. In contrast, the frequency of the intracranial bleeds in the placebo and enoxaparin group was similar when started 24 h after surgery. Agnelli *et al.* [9] suggest that compression stockings, together with enoxaparin (40 mg once daily, within 24 h after surgery), is the method of choice for prophylaxis against venous thromboembolism in the majority of patients undergoing elective neurosurgical procedures.

We too suggest that, until better evidence emerges, one should favour mechanical measures (antiembolism stockings, intermittent calf compression and physiotherapy) rather than pharmacological ones for the prevention of DVT in elderly patients with Parkinson's disease undergoing such procedures.

## References

- Rowe JG, Davies LE, Scott R, *et al.* Surgical complications of functional neurosurgery treating movement disorders: results with anatomical localisation. *J Clin Neurosci* 1999; **6**:36–37.
- Beric A, Kelly PJ, Rezai A, *et al.* Complications of deep brain stimulation surgery. *Stereotact Funct Neurosurg* 2001; **77**:73–78.
- Deogaonkar A, Avitsian R, Henderson JM, Schubert A. Venous air embolism during deep brain stimulation surgery in an awake supine patient. *Stereotact Funct Neurosurg* 2005; **83**:32–35.
- Jain V, Prabhakar H, Rath GP, Sharma D. Tension pneumocephalus following deep brain stimulation surgery with bispectral index monitoring. *Eur J Anaesthesiol* 2007; **24**:203–204.
- Voges J, Hilker R, Botzel K, *et al.* Thirty days complication rate following surgery performed for deep-brain-stimulation. *Mov Disord* 2007; **22**:1486–1489.
- Ibrahim A, Ashkan K, Smith M, Watkins L. Anticoagulation in a head-injured patient. *J R Soc Med* 2003; **96**:591–592.
- Norwood SH, McAuley CE, Berne JD, *et al.* Prospective evaluation of enoxaparin prophylactics for venous thrombo-embolism in patients with intracranial hemorrhagic injuries. *Arch Surg* 2002; **137**:696–701.
- Dickinson LD, Miller LD, Patel CP, Gupta SK. Enoxaparin increases the incidence of postoperative intracranial hemorrhage when initiated preoperatively for deep venous thrombosis prophylaxis in patients with brain tumors. *Neurosurgery* 1998; **43**:1074–1081.
- Agnelli G, Piovella F, Buonocristiani P, *et al.* Enoxaparin plus compression stockings compared with compression stockings alone in the prevention of venous thromboembolism after elective neurosurgery. *N Engl J Med* 1998; **339**:80–85.

DOI:10.1097/EJA.0b013e328320a68b

## Facilitating intubation during left molar approach for laryngoscopy

Rajesh Mahajan

Department of Anaesthesia, ASCOMS, Jammu, India

Correspondence to Dr Rajesh Mahajan, House no F-35, Patel Chowk, Jammu, Jammu and Kashmir 180001, India  
Tel: +91 191 2549948; e-mail: drmahajan@yahoo.com, drmahajanr@rediffmail.com

Received 31 October 2008 Accepted 4 November 2008

Editor,

We were interested in the recent article by Bozdogan *et al.* [1] regarding the use of left molar laryngoscopy to make difficult intubation easier. The authors rightly mentioned that the improved laryngeal view achieved with left molar laryngoscopy does not necessarily mean an improved success rate of tracheal intubation. This is attributable to the tongue being displaced to the right resulting in little space in the oral cavity to negotiate the tracheal tube into the glottic opening [1,2].

We have been using this technique and would like to suggest a few measures to increase the success rate of intubation while using left molar laryngoscopy. First, wherever feasible, a smaller size tracheal tube, size 6.5 for women and 7 for men, should be used as this can be negotiated more easily into the trachea. Further, it is always preferable to mount the tracheal tube on a malleable stylet. This tube with an internal stylet is passed from the centre or the right corner of the mouth with its concavity facing to the right side and advanced towards

the glottic. This avoids an inadvertent misdirection of the tube tip that is liable to occur when the tube contacts the walls of the narrow oropharyngeal passage created using left molar laryngoscopy. Further, when introduced from the right corner of the mouth, the tip of the tube faces towards the right and this results in a better view of the larynx [3]. In some cases, one may need to bend the stylet like a hockey stick to achieve the goal [3,4].

Alternatively or if use of the stylet does not succeed, use of a gum elastic bougie increases the success rate of negotiating the tracheal tube into the trachea. The use of a gum elastic bougie with an angled tip has been found to be especially useful when the operator recognizes some anatomical landmarks, but cannot direct the tip of the tracheal tube into the laryngeal inlet [4,5]. Once the gum elastic bougie is negotiated into the glottic aperture, the laryngoscope is left in position and the desired tube, preferably a flexometallic tube with a hemispherical bevel, is railroaded over the gum elastic bougie with a rotary motion. Use of a tube that minimizes the gap between the leading edge and the gum elastic bougie is known to facilitate insertion of the tracheal tube into the trachea [6]. Alternatively, after advancing the bougie in a left molar approach to a maximum of 45 cm [7], one can shift over to a conventional midline approach and negotiate the tracheal tube over the bougie in this position.

## References

- 1 Bozdogan N, Sener M, Bilen A, *et al*. Does left molar approach to laryngoscopy make difficult intubation easier than the conventional midline approach? *Eur J Anaesthesiol* 2008; **25**:681–684.
- 2 Yamamoto K, Tsubokawa T, Ohmura S, *et al*. Left-molar approach improves the laryngeal view in patients with difficult laryngoscopy. *Anesthesiology* 2000; **92**:70–74.
- 3 Smith M, Buist RJ, Mansour NY. A simple method to facilitate difficult intubation. *Can J Anaesth* 1990; **37**:144–145.
- 4 Dorsch JA, Dorsch SE. Tracheal tubes. In: Dorsch JA, Dorsch SE, editors. *Understanding anaesthesia equipment*. Baltimore: Williams & Wilkins; 1999. pp. 557–578.
- 5 Dogra S, Falconer R, Latto IP. Successful difficult intubation. Tracheal tube placement over a gum-elastic bougie. *Anaesthesia* 1990; **45**:774–776.
- 6 Makino H, Katoh T, Kobayashi S, *et al*. The effects of tracheal tube tip design and tube thickness on laryngeal pass ability during oral tube exchange with an introducer. *Anesth Analg* 2003; **97**:285–288.
- 7 Henderson JJ, Popat MT, Latto IP, Pearce AC, Difficult Airway Society. Difficult Airway Society guidelines for management of the unanticipated difficult intubation. *Anaesthesia* 2004; **59**:675–694.

DOI:10.1097/EJA.0b013e328320a6af

## Effective plexus anaesthesia in a patient with Ehlers–Danlos syndrome type III

Jessica T. Wegener, Jan Fräbldorf and Markus F. Stevens

Department of Anaesthesiology, Academic Medical Center, University of Amsterdam, Amsterdam, The Netherlands

Correspondence to Dr Markus F. Stevens, MD, DEAA, DESRA, Associate Professor of Anaesthesiology, Department of Anaesthesiology, Academic Medical

Center, Meibergdreef 9, University of Amsterdam, 1100DD Amsterdam, The Netherlands  
Tel: +31 20 566 5815; fax: +31 20 6979441;  
e-mail: m.f.stevens@amc.uva.nl

Received 6 November 2008 Revised 19 November 2008  
Accepted 26 November 2008

Editor,

Ehlers–Danlos syndrome type III (also called hypermobility type) is an autosomal dominant-inherited disease of the connective tissue with an incidence of 1:150 000 [1]. Although defects in the genes encoding for procollagen III (COL3A1) or tenascin-X (TNXB) have been suggested as possible candidates, up to now the precise defect for this genetic disease remains unknown [2]. From an anaesthesiologist's point of view, the most important features in patients with Ehlers–Danlos syndrome are vessel fragility, poor skin healing, excessive bleeding, spontaneous pneumothorax, joint dislocation including vertebral instability, valvular prolapse and – in type IV – spontaneous dissections and ruptures of major vessels. Thus, the vessel fragility and successive bleeding as well as scoliosis may be a relative contraindication against regional anaesthesia in favour of general anaesthesia, whereas cervical spine joint laxity, skin fragility, an increased risk of temporomandibular joint dislocation, laryngeal trauma and pneumothorax may push the pendulum back in the direction of regional anaesthesia. Furthermore, there have been studies showing that subcutaneous infiltration of lidocaine has a reduced time of action and that transcutaneous application of a eutectic mixture of lidocaine 2.5% and prilocaine 2.5% (EMLA, AstraZeneca, Södertälje, Sweden) did not produce sufficient analgesia [3]. Additionally, patients with benign joint hypermobility syndrome (incidence 1:10 000), a syndrome with clinical features overlapping with those of Ehlers–Danlos syndrome type III, and a possibly similar genetic background [2] report an increased ratio of local anaesthesia failure compared with controls [4]. In contrast to these observations, there have been case reports of successful epidural and spinal anaesthesia in patients with Ehlers–Danlos syndrome [5–7].

To our knowledge, there are no reports on peripheral nerve blocks in patients with Ehlers–Danlos syndrome. This would be interesting, especially in patients with Ehlers–Danlos syndrome type III, as, in these patients, the 'possibility of a resistance to local anaesthetics' has been stated [4]. Furthermore, these patients undergo repeated operations for their unstable joints, and it would be valuable to have knowledge about the possibility of peripheral nerve blockades in these patients.

## Case report

A 56-year-old female patient was scheduled to undergo a repeated arthroplasty of her left carpometacarpal joint. She was known to have a mitral valve prolapse, had

undergone an anterior cervical hernia operation C5/6 and C6/7 and was treated for arterial hypertension. She had been diagnosed with Ehlers–Danlos syndrome type III on clinical grounds several years earlier and had undergone several orthopaedic, traumatologic and plastic surgeries in the past. She had undergone surgery on her wrists four times under brachial plexus blockade anaesthesia. On detailed questioning, she reported that all regional blocks were sufficient and did wear off within reasonable time. Review of the anaesthesia files revealed that she had had an axillary block twice and a vertical infraclavicular block twice: all of them had been done within the previous 2 years with the help of a nerve stimulator. On three occasions she had received 40 ml mepivacaine 1.5% with epinephrine 1:200 000 and on the fourth occasion 30 ml levobupivacaine 0.375% for an axillary block. One axillary block had to be supplemented by a distal radial nerve block at the level of the elbow with 10 ml lidocaine 1%. Furthermore, all blockades were successful, and the operations had been performed without additional sedation or analgesia. The blockades with mepivacaine wore off 4–5 h after the injection while the patient was still in the recovery unit, whereas the blockade with levobupivacaine lasted 6–8 h. Thus, she had a completely normal history of peripheral nerve blockades with a typical duration of blocks.

In contrast, she admitted that, during several dental procedures, the local anaesthetic effect (articaine) was of rather unusual short duration of approximately 15 min according to her dentist. It was her explicit wish to undergo a further hand operation under regional anaesthesia, because she had had a bad experience with urinary retention after an earlier general anaesthesia. Therefore, she gave informed consent for a supraclavicular blockade with a peripheral nerve catheter for postoperative pain therapy and publication of the case.

Thus, we performed a brachial plexus blockade under ultrasound guidance (12 MHz linear probe, LOGIQ e, GE Medical Systems, China) via a supraclavicular approach using an in-plane technique. The brachial plexus could be identified above the subclavian artery and above the first rib. With an in-plane technique, the cannula was visualized the whole time and the spread of local anaesthetic checked and accordingly adjusted. Twenty millilitres of mepivacaine 2% was injected through the needle and then catheter advanced 3 cm above the tip of the needle (Contiplex D; B. Braun, Melsungen, Germany). Finally, the correct positioning of the catheter was checked by a test injection of a minuscule air bubble to visualize the end of the catheter and 1 ml lidocaine 1% in order to check adequate spread of the local anaesthetic around the plexus. Although contact with all visible vessels was avoided, there was some bleeding from the puncture site necessitating a

local compression for a couple of minutes. Thereafter, no further bleeding or swelling was seen.

The brachial plexus was blocked completely within 15 min, and the patient underwent the operation without any additional sedation or analgesia. She received satisfactory postoperative pain therapy via the brachial plexus catheter for 36 h (bupivacaine 0.125% with an infusion rate of 6 ml h<sup>-1</sup>, visual analogue scale at all times <20%) without any additional rescue medication and went home pain free on the second postoperative day.

## Discussion

This is the first description of peripheral nerve blocks in a patient with Ehlers–Danlos syndrome. The case shows that peripheral regional anaesthesia is an option in these patients making the ‘possibility of resistance to local anaesthesia’ [4] in this patient group unlikely.

Ehlers–Danlos syndrome is a heterogeneous group of inherited diseases characterized by abnormal connective tissue. Because of the life-threatening fragility of the great vessels in type IV, this form has received considerable attention from anaesthesiologists [7,8]. In contrast, type III has received little interest, though a reduced efficacy of local anaesthetics could be demonstrated. The infiltration anaesthesia with lidocaine is shortened and, with a eutectic mixture of lidocaine and prilocaine, sufficient analgesia could not be reached. Furthermore, 58% of patients with benign joint hypermobility syndrome (which is regarded by some authorities as identical to Ehlers–Danlos type III [2,9]) reported experiencing an ineffective local anaesthesia in the past, whereas this was reported by only 21% of the matched controls [4]. Thus, at least with transcutaneous and subcutaneous infiltration of local anaesthetics, there is a reduced efficacy. This may be due to the altered texture of the cutaneous and subcutaneous connective tissue leading to a faster spread or systemic resorption or both of local anaesthetics. In contrast, case reports have documented a normal effectiveness during spinal and epidural anaesthesia [5,7]. To our knowledge, this is the first case report of four successful plexus brachialis blockades of normal duration in a patient with Ehlers–Danlos syndrome type III. Possibly in these locations, the distribution and or resorption of local anaesthetics are unaltered through the abnormal connective tissue. Certainly, the nerves of patients with Ehlers–Danlos type III or benign joint hypermobility syndromes are not ‘resistant’ to local anaesthetics as stated by some authors [4]. All voltage-gated sodium channels of eukaryotes have a highly conserved region that binds to local anaesthetics [10]. Beyond that, the genetic variations suggested to induce Ehlers–Danlos syndrome type III (mutations in procollagen III or in tenascin-X) have no influence on the sensitivity of the voltage-gated sodium channel. Thus, the reason for the decreased effectiveness of

transcutaneous or subcutaneous local anaesthesia is likely to be an altered pharmacokinetics rather than a change in pharmacodynamics.

Another problem in patients with Ehlers–Danlos syndrome is the fragility of blood vessels and the pleurae. Nowadays, injury to sensitive surrounding structures such as great vessels or the pleura may be avoided by the use of ultrasound-guided regional anaesthesia [11]. Naturally, damage to small vessels cannot be avoided and, therefore, our patient had a minor bleed next to the catheter at the end of the procedure. We chose an ultrasound-guided supraclavicular in-plane approach, because supraclavicularly the plexus brachialis is most superficial to the skin and the cannula can be visualized the whole way with minimal tissue damage. Furthermore, the neural structures are very compact there, avoiding multiple redirection of the needle as, for example, with an axillary approach. However, with an ultrasound-guided technique, the chance of injuring sensitive structures can only be lower but may never be avoided completely.

In conclusion, peripheral nerve blocks in a patient with Ehlers–Danlos syndrome type III worked as effectively as in normal persons, whereas infiltration anaesthesia – as described in the literature – is less effective. Ultrasound-guided regional anaesthesia may help to avoid injury to vessels or the pleurae, which are extremely fragile structures in these patients.

## References

- Baum VC, O'Flaherty JE. Ehlers–Danlos syndrome. In: Baum VC, O'Flaherty JE, editors. *Anesthesia for genetic, metabolic, & dysmorphic syndromes of childhood*. Philadelphia, Pennsylvania: Lippincott Williams & Wilkins; 2007. pp. 115–118.
- Zweers MC, Kucharekova M, Schalkwijk J. Tenascin-X: a candidate gene for benign joint hypermobility syndrome and hypermobility type Ehlers–Danlos syndrome? *Ann Rheum Dis* 2005; **64**:504–505.
- Arendt-Nielsen L, Kaalund S, Bjerring P, Hogsaa B. Insufficient effect of local analgesics in Ehlers Danlos type III patients (connective tissue disorder). *Acta Anaesthesiol Scand* 1990; **34**:358–361.
- Hakim AJ, Grahame R, Norris P, Hopper C. Local anaesthetic failure in joint hypermobility syndrome. *J R Soc Med* 2005; **98**:84–85.
- Kuczowski KM, Benumof JL. Cesarean section and Ehlers–Danlos syndrome: choice of anesthesia. *Int J Obstet Anesth* 2002; **11**:222–224.
- Dill-Russell P, Jones LS. Anaesthesia for caesarean section in a patient with Ehlers–Danlos syndrome and mitral valve prolapse. *Int J Obstet Anesth* 2001; **10**:192–197.
- Campbell N, Rosaeg OP. Anesthetic management of a parturient with Ehlers Danlos syndrome type IV. *Can J Anaesth* 2002; **49**:493–496.
- Solan K, Davies P. Anaesthetic and intensive care management of a patient with Ehlers–Danlos type IV syndrome after laparotomy. *Anaesthesia* 2004; **59**:1224–1227.
- Buckingham RB, Braun T, Harinstein DA, et al. Temporomandibular joint dysfunction syndrome: a close association with systemic joint laxity (the hypermobile joint syndrome). *Oral Surg Oral Med Oral Pathol* 1991; **72**:514–519.
- Nau C, Wang GK. Interactions of local anesthetics with voltage-gated Na<sup>+</sup> channels. *J Membr Biol* 2004; **201**:1–8.
- Gray AT. Ultrasound-guided regional anaesthesia: current state of the art. *Anesthesiology* 2006; **104**:368–373.

## A useful device for difficult nasal tracheal intubation in China

Hong Jiang, Yu Sun and Yesen Zhu

Department of Anesthesiology, Shanghai Ninth People's Hospital affiliated to Shanghai Jiao Tong University School of Medicine, Shanghai, China

Correspondence to Hong Jiang, PhD, MD, Department of Anesthesiology, Shanghai Ninth People's Hospital affiliated to Shanghai Jiao Tong University School of Medicine, Zhizaoju Road 639, Shanghai 200011, China  
Tel: +8621 63138341; fax: +8621 63163572;  
e-mail: dr.jianghong@yahoo.com.cn


Received 30 November 2008 Accepted 2 December 2008

Editor,

There are a wide variety of options for anticipated difficult intubation, and the fiberoptic bronchoscopes and intubation laryngeal mask airway have been advocated as effective tools for difficult intubation [1,2]. At times, when none of the instruments is available, alternatives need to be considered. The blind intubation device (BID), manufactured by Anhui Xiaoshan Hygienic Material Co Ltd, Jixi County, China, is a new single-use intubation device and seems to be one such alternative in our institute.

The BID (Fig. 1) consists of a battery cell, a light-guided catheter and an oesophageal tube. The light-guided catheter is a 70 cm long flexible wire, with an external diameter of 3.5 mm and a fixed anterior curvature of 30° at the tip. At the anterior tip, there is also a small light bulb. The oesophageal tube is a graduated, single-lumen polyvinyl chloride (PVC) tube, with an inner diameter of 6.0 mm and a round dead end. At a distance of 6 cm from the dead end, there is an ellipse gap with a 30° ramp at its bottom. Over the ellipse gap is a cuff which can be inflated. The intubation technique (Fig. 2) is easy.

Fig. 1



The blind intubation device, the battery cell (B), the light-guided catheter (L) and the oesophageal tube (E).

DOI:10.1097/EJA.0b013e328324044e

Fig. 2

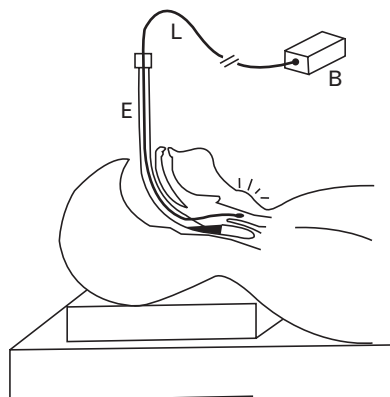


Illustration of the blind intubation device application. The oesophageal tube is inserted into the oesophagus, and the ellipse gap is towards the glottis. Thereafter, the light-guided catheter slides into the glottis.

The patient is prepared with nasal decongestants. Routine monitoring is applied. After intravenous administration of a sedative dosage of fentanyl and midazolam, the procedure of adequate topical anaesthesia of the nares and nasopharynx is performed with 7% lidocaine spray. After preparing the oesophageal tube with lubricant, blind nasal oesophageal intubation is performed in the 'sniff position'. The patient is asked to swallow when resistance to advancement is felt. After being inserted into the oesophagus, the oesophageal tube is withdrawn slowly until the tubular sound is heard clearly by the anaesthesiologist, which means that the ellipse gap is pointed exactly towards the glottis. Thereafter, the light-guided catheter is inserted into the oesophageal tube. The oesophageal tube can be adjusted slowly by the anaesthesiologist according to the location of the light spot until a bright light spot passes through the front of the neck, which means the light-guided catheter has entered into the glottis. Thereafter, the oesophageal tube is withdrawn carefully. Once the oesophageal tube has been removed, the endotracheal tube is guided and inserted into the trachea over the light-guided catheter. The correct position is confirmed with auscultation and with confirmation of end-tidal capnography.

The BID is a battery-operated disposable device and appears to be safe and reliable for difficult nasal tracheal intubation. It is useful in patients with limited mouth opening and even in patients with no mouth opening. It is also helpful in patients who have limited or no neck mobility. The PVC oesophageal tube can be easily used in nasal oesophageal intubation. Below the gap, the 30° ramp makes the tip of the light-guided catheter slide into the glottis easily. Additionally, the oesophageal tube allows for oxygenation and ventilation before tracheal intubation is attempted, and the oesophageal tube can be used as the sole airway without tracheal intubation when

its cuff is being inflated. The major limitation of the BID is failure to view the light spot in some burns patients with severe scarring in the neck. Second, the inner diameter of the oesophageal tube is 6.0 mm so the size of the endotracheal tube should not be less than 6.0 mm. However, further studies are required to compare the BID with other difficult intubation devices.

## References

- 1 Ovassapian A. The flexible bronchoscope: a tool for anesthesiologists. *Clin Chest Med* 2001; **22**:281–299.
- 2 Brimacombe JR. Difficult airway management with the intubating laryngeal mask. *Anesth Analg* 1997; **85**:1173–1175.

DOI:10.1097/EJA.0b013e328324e95f

## The Bonfils intubation fibrescope: clinical evaluation and consideration of the learning curve

Ulisse Corbanese and Mauro Morossi

Department of Anesthesia and Intensive Care, Ospedale S. Maria dei Battuti, Conegliano, Italy

Correspondence to Dr Ulisse Corbanese, Department of Anesthesia and Intensive Care, Ospedale S. Maria dei Battuti, Via B. Bisagno, 31015 Conegliano, Italy  
Tel: +39 0438663233; fax: +39 02700514528; e-mail: ulisse.md@mailcity.com

Received 13 September 2008 Revised 21 November 2008

Accepted 27 December 2008

The Bonfils rigid fibrescope (Karl Storz GmbH, Tuttlingen, Germany) is an instrument used to perform tracheal intubation. Although proven to be effective both in patients with normal airways and in those with difficult airways [1–6], relatively few papers about the Bonfils fibrescope are currently available in the literature.

The Bonfils fibrescope is a rigid 40 cm long endoscope with a 40° curved tip, on which a tracheal tube with an internal diameter of at least 5.5 mm can be loaded, and a 15 mm tracheal tube adapter that allows the position of the distal end of the tube to be adjusted a few millimetres beyond the tip of the fibrescope. The instrument view through the end of the tracheal tube and its shape make it easier to locate the laryngeal inlet in patients with difficult airways [1,6].

Generally, about 20 [1] elective intubations are considered to provide sufficient experience for its standard clinical use, whereas, for difficult airways, experience of at least 50 cases has been suggested [6]. However, these recommendations are not so well documented, as series of intubations of a single anaesthesiologist are seldom reported [1,2].

The aim of this study is two-fold: assessing the effectiveness of the Bonfils fibrescope in a consecutive series of 100 intubations of a single anaesthesiologist and

analysing the learning process of the technique. The study was approved by the Institutional Ethical Committee. Informed consent was obtained from all patients. Patients without criteria for difficult intubation [7] were eligible unless emergency surgery was needed.

The Bonfils fibrescope was connected to a video monitor system. In order to prevent fogging, an O<sub>2</sub> flow was administered via the connector fitting onto the tracheal tube adapter.

Patients were placed in the sniffing position and monitored with ECG, SpO<sub>2</sub>, capnography, and noninvasive blood pressure. Atropine (0.005–0.01 mg kg<sup>-1</sup>) and fentanyl (1–1.5 µg kg<sup>-1</sup>) were administered intravenously a few minutes before the procedure.

After preoxygenation, anaesthesia was induced with thiopental (3–5 mg kg<sup>-1</sup>) or propofol (2–2.5 mg kg<sup>-1</sup>), and, if ventilation with a face mask was successful, patients were paralysed. The instrument was introduced by the dominant hand into the oral cavity using a midline approach, whereas the nondominant hand lifted the mandible to open the oropharynx [1]. Once the tip of the tube was adjacent to the vocal cords, the mandible traction was released and the tube was passed down into the trachea. Intubation attempts were interrupted whenever SpO<sub>2</sub> showed O<sub>2</sub> desaturation or if any further attempt was considered dangerous or futile.

If the chin-lift manoeuvre proved to be inadequate, the Macintosh laryngoscope could be used along with the Bonfils fibrescope. Total intubation times were the sum of each intubation attempt, starting from the moment the Bonfils fibrescope was first touched until an appropriate capnograph trace appeared (or attempts were discontinued) in seconds (s).

The study was subdivided into two phases: the learning phase up to the 50th intubation and the standard phase afterwards [6]. Each phase was further subdivided in five groups of 10 intubations each to evaluate the progress of learning. Comparisons were made using the chi-squared test, Student's *t*-test, Mann–Whitney *U* test, and Kruskal–Wallis test with post-hoc Bonferroni correction of *P*, as appropriate.

One hundred consecutive patients were included. Mean ± SD age was 60.3 ± 17.0 years, 59% were women, median Mallampati class was 1 [interquartile range (IQR), 1–2], and mean thyromental and interincisor distances were 7.6 ± 1.1 and 4.3 ± 0.6 cm, respectively.

Intubation was successful in 98 patients [98%; 95% confidence interval (CI), 93.5–99.6], with a median intubation time of 30 s (IQR, 25–40 s). Intubation was successful at the first attempt in 89 patients (90.8%; 95% CI,

83.8–95.4), whereas two and three attempts were needed in six (6.1%; 95% CI, 2.5–12.2) and three patients (3.1%; 95% CI, 0.7–8.1), respectively. Failed intubations, all without the aid of a laryngoscope, occurred in the first and third patient. Both patients were subsequently intubated without difficulty using a Macintosh laryngoscope. In two patients, Bonfils fibrescope intubations succeeded only with the aid of a Macintosh laryngoscope.

There was no evidence of airway trauma (0%; 95% CI, 0.0–2.9). The most frequent problems encountered were fogging (12%; 95% CI, 6.6–19.5), difficulties in getting the Bonfils fibrescope tip under the epiglottis (7%; 95% CI, 3.1–13.3), difficult advancement of the tube due to inadequate lubrication (6%; 95% CI, 2.4–12.0), and gross mucous secretions obscuring laryngeal anatomy (5%; 95% CI, 1.8–10.7).

The learning and standard phases differed only in terms of median intubation time (*P* = 0.011) and number of attempts (*P* = 0.022). Regarding these aspects, there was larger data dispersion during the learning phase, as demonstrated by the coefficients of variation and the trend of interquartile ranges (Table 1). Moreover, the Kruskal–Wallis test detected significant differences between the first group (A) and groups B, C, and E for intubation times and groups C and E for the number of attempts. There were no statistically significant differences among the groups of the standard phase.

The literature reports five series (*n* = 235) of intubations performed with the Bonfils fibrescope on patients with normal airways. The success rates ranged from 86.1 to 100%, with median intubation times ranging from 25 to 80 s [1–5]. Our data compare well with these reports, although the operator's experience varies among different studies. The two failures in our study were actually due to inexperience, as both patients were successfully intubated without difficulty with a Macintosh laryngoscope.

Minor difficulties were similar to those encountered by other authors [1,2], fogging being the most frequent. Only an O<sub>2</sub> flow of at least 8 l min<sup>-1</sup> eliminated the problem, but antifogging agents are probably more efficient [1,2]. The incidence of gross secretion reducing the view was significantly lower among our patients (5 vs. 30% [1]): an antisialogogue premedication should always be considered, particularly in patients with a difficult airway.

Once the manoeuvres to open the oropharynx, by lifting the mandible, are learned, the aid of a Macintosh laryngoscope is rarely necessary. Although we did not detect any evidence of traumatic injury, our data allow only the inference of a maximum rate of dental or airway trauma of 2.9% (with a confidence interval of 95%).

Table 1 Median number of attempts and intubation times throughout the series of 100 intubations

Phase	Learning (1st to 50th case)										Standard (51st to 100th case)									
	A	B	C	D	E	F	G	H	I	J	A	B	C	D	E	F	G	H	I	J
Attempts (IQR, VC)	1 (1-1, 50.0)										1 (1-1, 19.0)									
Intubation time (IQR, VC)	35 (25-53.5, 63.3)										28 (25.7-33.2, 51.5)									
Attempts (IQR)	3 (1-3)	1 (1-1)	1 (1-1)	1 (1-1)	1 (1-1)	1 (1-1)	1 (1-1)	1 (1-1)	1 (1-1)	1 (1-1)	3 (1-3)	1 (1-1)	1 (1-1)	1 (1-1)	1 (1-1)	1 (1-1)	1 (1-1)	1 (1-1)	1 (1-1)	1 (1-1)
Kruskal-Wallis test	$P=0.001$ (post-hoc tests*: AC $P=0.047$ ; AE $P=0.047$ )																			
Intubation time (IQR)	95 (50-115)	25 (25-41.2)	30 (25-40.5)	40 (28.7-59)	33 (22-51.5)	28 (26.7-34)	28.5 (25.7-36.2)	29 (24.5-35.5)	28 (23-33)	29 (26.2-32.7)	95 (50-115)	25 (25-41.2)	30 (25-40.5)	40 (28.7-59)	33 (22-51.5)	28 (26.7-34)	28.5 (25.7-36.2)	29 (24.5-35.5)	28 (23-33)	29 (26.2-32.7)
Kruskal-Wallis test	$P=0.004$ (post-hoc tests*: AB $P=0.026$ ; AC $P=0.010$ ; AE $P=0.047$ )										$P=0.984$									

A to J, groups of 10 consecutive intubations. IQR, interquartile range; VC, coefficient of variation. \* Mann-Whitney U tests with the Bonferroni correction.

Our results support the theory that about 20 intubations provide sufficient experience for clinical use in patients with normal airways [1], as intubation times and number of attempts significantly decreased after the 10th. No significant differences were detected among the groups from B to E, nor among the groups of the standard phase (Table 1), whereas coefficients of variation and IQR were larger for groups of the learning phase. These data suggest that no further learning occurred after the 50th intubation, indirectly supporting the definition of 'experienced user' suggested by Bein *et al.* [6].

This study has several limitations, the most important being its observational and uncontrolled design and the fact that it reports the experience of a single operator. However, our study corroborates the good results reported in the literature with the Bonfils fibrescope, and it confirms the steep learning curve of this technique.

## References

- Halligan M, Charters P. A clinical evaluation of the Bonfils intubation fibrescope. *Anaesthesia* 2003; **58**:1087-1091.
- Wong P, Lawrence C, Pearce A. Intubation times for using the Bonfils intubation fibrescope. *Br J Anaesth* 2003; **91**:757.
- Rudolph C, Schlender M. Clinical experiences with fiber optic intubation with the Bonfils intubation fiberscope. *Anaesthesiol Reanim* 1996; **21**:127-130.
- Wahlen BM, Gercek E. Three-dimensional cervical spine movement during intubation using the Macintosh and Bullard laryngoscopes, the Bonfils fibrescope and the intubating laryngeal mask airway. *Eur J Anaesthesiol* 2004; **21**:907-913.
- Rudolph C, Schneider JP, Wallenborn J, Schaffranietz L. Movement of the upper cervical spine during laryngoscopy: a comparison of the Bonfils intubation fibrescope and the Macintosh laryngoscope. *Anaesthesia* 2005; **60**:668-672.
- Bein B, Yan M, Tonner PH, *et al.* Tracheal intubation using the Bonfils intubation fibrescope after failed direct laryngoscopy. *Anaesthesia* 2004; **59**:1207-1209.
- Petrini F, Accorsi A, Adrario E, *et al.* Recommendations for airway control and difficult airway management. *Minerva Anesthesiol* 2005; **71**:617-657.

DOI:10.1097/EJA.0b013e328328f572