

A ventral rotational skin flap to improve cosmesis and avoid chordee recurrence in epispadias repair

J.L. PIPPI SALLE, R. JEDNAK, J.P. CAPOLICCHIO, I.M.P. FRANÇA*, A. LABBIE† and R. GOSALBEZ†

*Divisions of Paediatric Urology, Montreal Children's Hospital-McGill University Health Center, Montreal, Canada, and †Miami Children's Hospital, Miami, USA, and *The Department of Paediatric Surgery, Hospital Fernando Fonseca, Amadora, Portugal*

Objective To describe a technical modification that facilitates dorsal skin closure, improves cosmesis and eliminates chordee recurrence secondary to contracture of the dorsal penile skin in the repair of epispadias.

Patients and methods Eleven patients with penopubic epispadias (mean age 1.8 years) had the epispadias repaired using a modified ventral penile skin flap. Four patients had isolated epispadias and seven had had a previous primary closure of bladder exstrophy. Nine patients underwent the Cantwell-Ransley technique, leaving the meatus in a glanular position. Two patients were repaired using the penile disassembly technique of Mitchell and Bägli, because they had a short urethral plate. A ventral island skin flap was fashioned, starting at the base of the penis. Dissection was carried ventrally

into the scrotum to allow for adequate dorsal flap transposition. The flap was rotated laterally to shift the suture line from the midline and to cover the dorsal aspect of the penis with untouched penile shaft skin. Redundant ventral foreskin was discarded.

Results All patients had an uneventful course after surgery. Dorsal penile skin was viable in every case and no patient developed recurrence of chordee or a urethrocutaneous fistula. The cosmetic result was excellent in all patients.

Conclusions Dorsal skin closure using lateral rotation of ventral penile skin flap improves cosmesis after epispadias repair and eliminates the recurrence of chordee secondary to midline dorsal scarring.

Keywords epispadias, bladder exstrophy, penis, repair

Introduction

Several previously described technical modifications have allowed for a significant improvement in the outcome of epispadias repair since Cantwell first described his technique in 1895 [1]. Specific technical challenges include reducing the incidence of urethrocutaneous fistulae, eliminating chordee recurrence and optimizing penile skin coverage. Modifications such as rotation of the corpora cavernosa and ventralization of the neourethra have significantly reduced the incidence of urethrocutaneous fistulae and recurrent chordee [2,3]. As techniques of urethroplasty and orthoplasty for epispadias have developed the issue of penile skin coverage has also been addressed using several approaches. The use of Byars' flaps derived from the ventral prepuce has been described, but irregular dorsal coverage and the development of a dorsal midline scar results in less than ideal cosmesis. In addition, scar retraction may induce recurrence of dorsal chordee [4,5]. Transverse island pedicle flaps based on the ventral prepuce have been used for both urethral reconstruction and dorsal skin coverage [2,6–8]. Unfortunately,

this preputial flap is often redundant and differs in appearance from the normal penile skin. Furthermore, the ventral penile skin remaining after elevating the pedicled flap may be of doubtful viability as the principle arterial supply is diverted away during dissection. The use of scrotal skin to cover the dorsal penile skin defect has also been described, but clearly the use of hair-bearing skin achieves a less than ideal cosmetic result [9]. To improve cosmesis and avoid midline scarring we describe a simple modification using a ventral penile skin flap, which diminishes dorsal penile scarring and results in improved cosmesis after epispadias repair.

Patients and methods

Eleven boys (mean age 1.8 months, range 2 days to 24 months) had their epispadias repaired in two large referral centres. Preoperative imaging included abdominal ultrasonography in all patients. Voiding cystourethrography and/or urodynamic studies were conducted in three patients. The epispadias was repaired under general anaesthesia and a supplemental caudal block in all patients. Nine boys had their epispadias repaired using the Cantwell-Ransley technique [2], with no cavernocavernostomy. Two patients with a short

Accepted for publication 30 August 2002

urethral plate were repaired using the penile disassembly technique of Mitchell and Bägli [3]. Dorsal skin coverage was achieved using penile skin rather than the redundant ventral prepuce. The ventral penoscrotal junction was identified and the incision line demarcated (Fig. 1). The ventral skin was incised transversely sparing the vascular supply to the penile and preputial skin. The island flap of penile skin was then developed by mobilizing the scrotal skin from the underlying dartos fascia vascular pedicle in the direction of the scrotum (Fig. 2). The technique for dis-

section was analogous to that for preputial island flap development in hypospadias repair. Dissection was continued until a flap with sufficient mobility was fashioned to achieve a 90° rotation of the flap and allow lateral placement of the longitudinal shaft skin suture line at the 3 or 9 o'clock positions (Fig. 3). Excess preputial skin was discarded and the skin edges approximated. Several sutures were placed anchoring the flap base to the prepubic tissue. Similarly the flap was anchored to the underlying corpora to keep the penile shaft exteriorized (Fig. 4). Excess skin

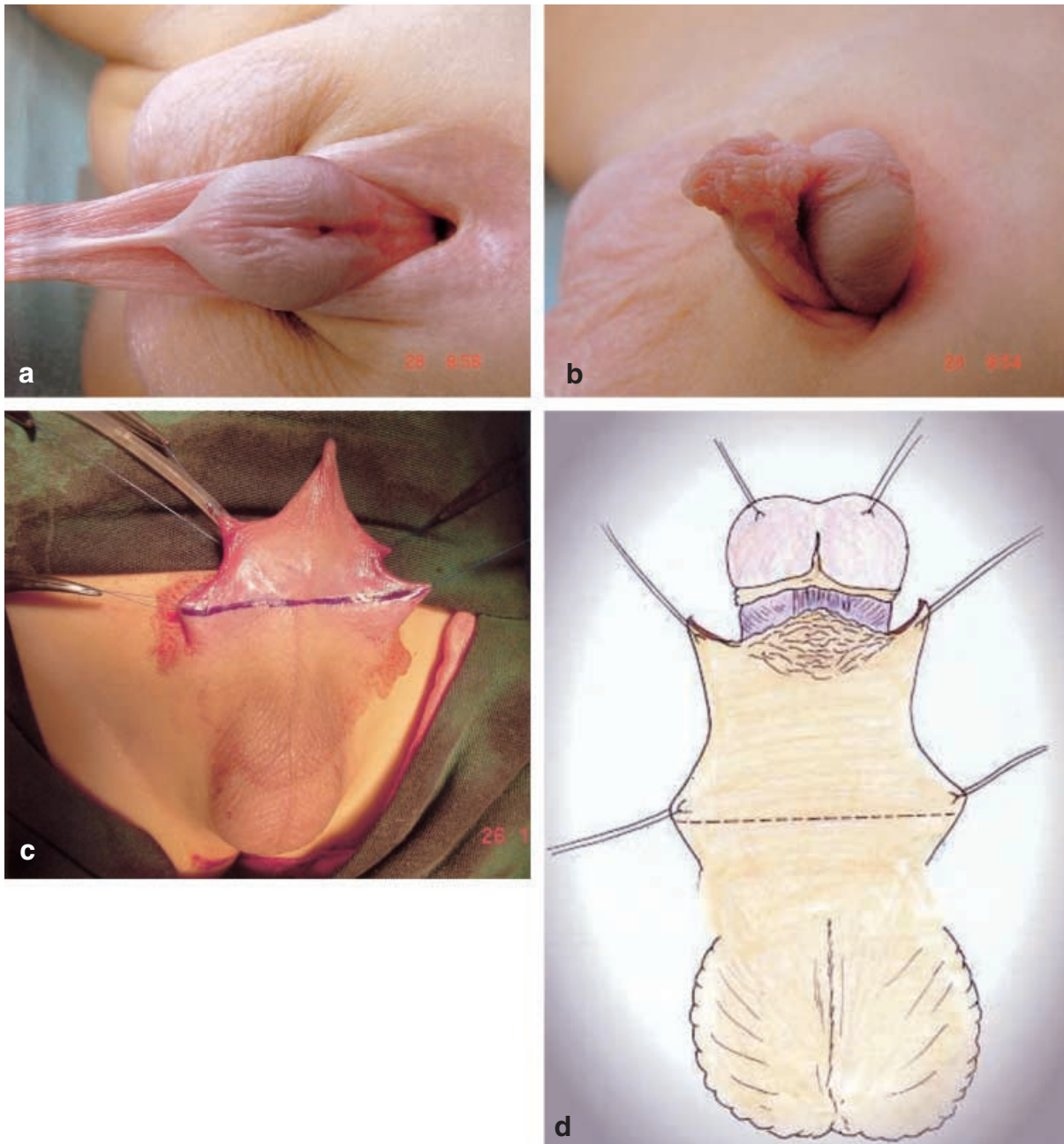


Fig. 1. a,b, Penopubic epispadias in a 12-month-old boy; c,d, The ventral penoscrotal junction is identified and the incision line demarcated.

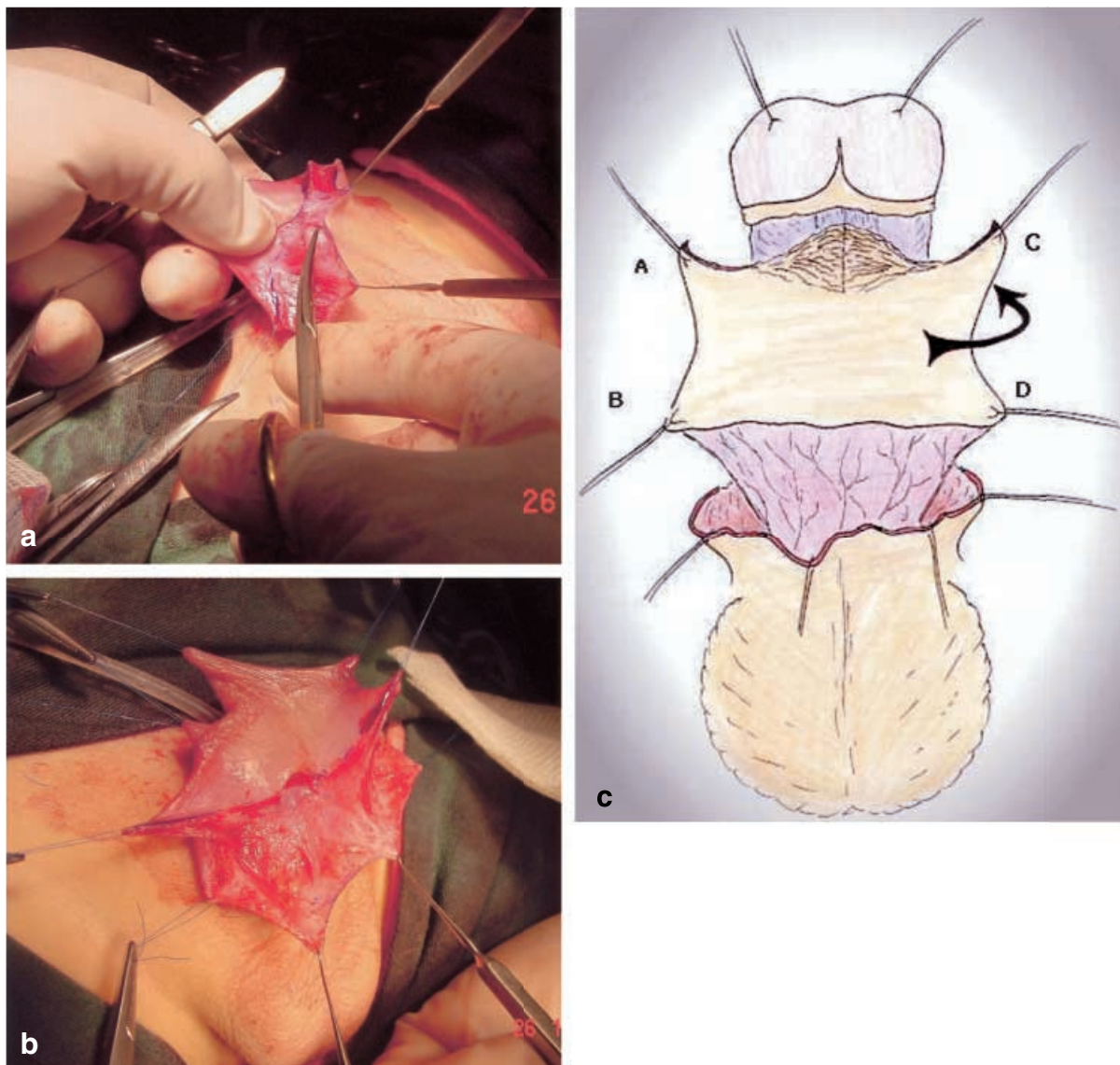


Fig. 2. a,b,c, Dissection of the ventral penile skin flap is directed toward the penoscrotal junction. Mobilization is continued until a flap with sufficient mobility is fashioned to enable dorsal rotation and lateral placement of the longitudinal shaft skin suture line.

from the penoscrotal area was removed, which allowed for a more anatomically normal approximation between the scrotum and ventral penile base.

Results

All patients had an excellent outcome with a mean follow-up of 8.2 months. No patient developed a urethrocutaneous fistula or recurrence of chordee. Penile skin coverage using the ventral shaft skin achieved an excellent cosmetic result (Fig. 5). Straight erections were noted in some patients, but the age of the patients precluded an evaluation of the functional status.

Discussion

The subject of dorsal penile skin coverage in epispadias repair has received significantly less attention than both urethroplasty and orthoplasty. Nevertheless, it can present a significant challenge to the urologist and all too often the cosmetic result is far from ideal. We describe a simple and effective technical modification for epispadias repair, which allows for the use of ventral penile rather than preputial skin. It results in a lateralized suture line, thereby avoiding the contribution of dorsal midline scarring to the recurrence of chordee. The use of penile shaft skin, which is smooth and firm, rather than the prepuce,

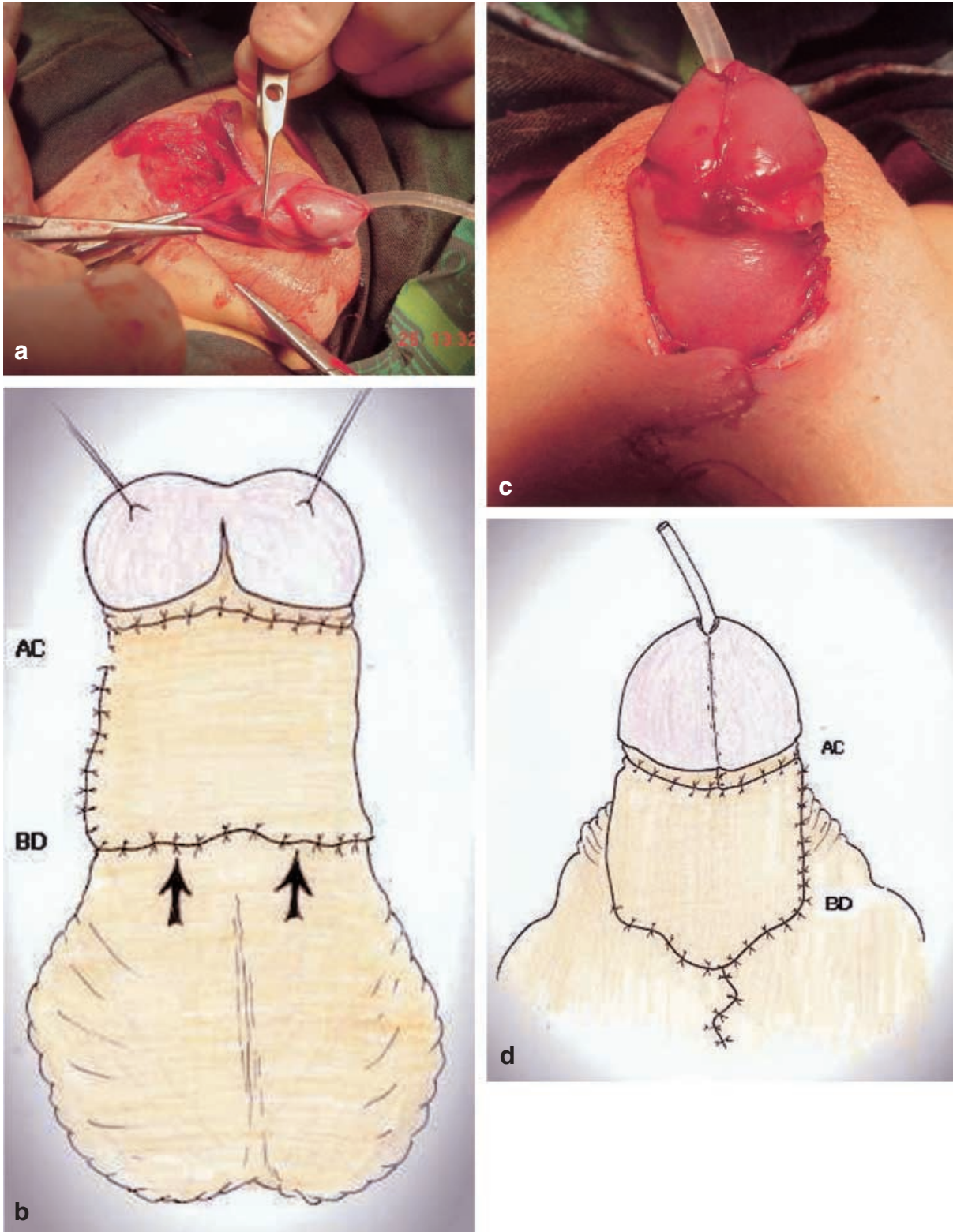


Fig. 3. a,b Rotation of the ventral penile skin flap allows for lateral placement of the suture line. Notice the cephalad mobilization of the peno-scrotal junction which enables closer approximation of the scrotum to the base of the penis; c,d The dorsal aspect of the penis. The absence of a midline penile scar eliminates the contribution of scar contracture to chordee recurrence.

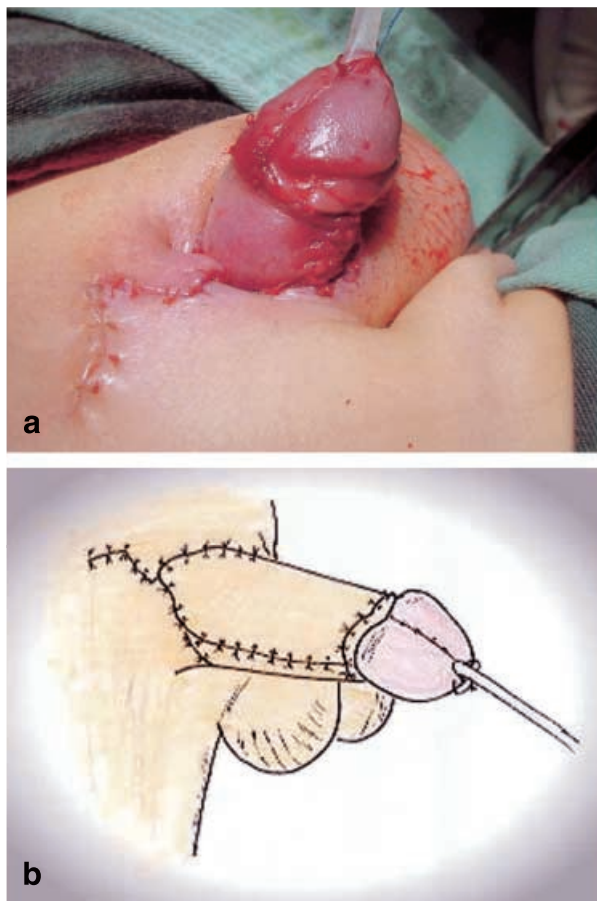


Fig. 4. a,b Lateral view of the penis shows placement of the suture line.

cosmetically gives the penis a more natural appearance dorsally. It can be argued that a stretched preputial island flap is also effective and achieves satisfactory cosmesis, but our previous experience using this type of flap has frequently resulted in a redundant and folded appearance to the skin. Subsequent revisions were required in many of these patients to improve cosmesis. Furthermore, the present technique creates only one laterally placed suture line rather than the two dorsally placed suture lines created with the preputial island flap.

The aesthetic benefits offered by the penile skin pedicle flap are not simply limited to a more cosmetically appealing phallus. In the normal situation the upper scrotum and ventral penile base are closely approximated. However, patients with epispadias typically have a marked separation between the scrotum and ventral penile base, with a wide intervening strip of skin separating them. Use of the ventral penile skin flap allows for scrotal elevation and a closer and more natural appearing approximation between the scrotum and penis.



Fig. 5. The result 13 months after epispadias repair in a patient with bladder exstrophy.

It is important to extend flap dissection sufficiently such that satisfactory rotational mobility can be achieved without subjecting the flap to excessive tension. Aggressive and extensive mobilization must be avoided to prevent vascular damage and skin ischaemia. Finally, it is advisable to anchor the penile skin to the pubic ligaments and the corpora along the penile shaft to improve the cosmetic result. This is similar to the technique used for repair of a buried penis. This manoeuvre results in a more prominent and exteriorized penis. From our initial experience we feel confident that this can be a useful technique to reconstructive surgeons involved in epispadias repair.

References

- 1 Cantwell FV. Operative technique of epispadias by transplantation of the urethra. *Ann Surg* 1895; **22**: 689–94
- 2 Ransley PG, Duffy PG, Wollin M. Bladder exstrophy closure and epispadias repair. In Spitz L, Nixon HH eds, *Operative Surgery – Pediatric Surgery*, 4th edn. London: Butterworths, 1988: 620–32
- 3 Mitchell ME, Bägli DJ. Complete penile disassembly for epispadias repair: the Mitchell technique. *J Urol* 1996; **155**: 300–4
- 4 Hinman F Jr. A method of lengthening and repairing the penis in exstrophy of the bladder. *J Urol* 1958; **79**: 237–41
- 5 Hendren WH. Penile lengthening after previous repair of epispadias. *J Urol* 1979; **121**: 527–34
- 6 Thomalla JV, Mitchell ME. Ventral preputial island flap technique for the repair of epispadias with or without exstrophy. *J Urol* 1984; **132**: 985–7
- 7 Monfort G, Morisson-Lacombe G, Guys JM, Coquet M. Transverse island flap and double flap procedure in the treatment of congenital epispadias in 32 patients. *J Urol* 1987; **138**: 1069–71

- 8 Diamond DA, Ransley PG. Male epispadias. *J Urol* 1995; **154**: 2150–5
- 9 Khanna NN. Techniques of epispadias repair. *Plast Reconstr Surg* 1973; **52**: 365–9

Authors

J.L. Pippi Salle, MD, PhD, Associate Professor and Director.
R. Jednak, MD, Assistant Professor.

J.P. Capolicchio, MD, Assistant Professor.
I.M.P. França, MD, Paediatric Surgeon.

A. Labbie, MD, Co-director.

R. Gosalbez, MD, Co-director.

Correspondence: J.L. Pippi Salle, Paediatric Urology, The Montreal Children's Hospital – McGill University Health Center, 2300 Tupper Street, Rm. C5.27, Montreal, Quebec, Canada H3H 1P3.

e-mail: mchurology@muhc.mcgill.ca