

SHORT COMMUNICATION

# Congenital ocular motor apraxia

S. GONÇALVES CARRASQUINHO<sup>1</sup>, S. TEIXEIRA<sup>1</sup>, A. CADETE<sup>2</sup>, M. BERNARDO<sup>1</sup>, P. PÊGO<sup>1</sup>, I. PRIETO<sup>1</sup>

<sup>1</sup>Paediatric Ophthalmology Department

<sup>2</sup>Physical Medicine and Rehabilitation Department, Hospital Fernando Fonseca, Lisboa - Portugal

**PURPOSE.** *Congenital ocular motor apraxia is a rare disease characterized by defective or absent voluntary and optically induced horizontal saccadic movements. Jerky head movements or thrusts on attempted lateral gaze are a compensatory sign. Most affected children have delayed motor and speech development. Cases associated with systemic diseases, neurologic maldevelopment, metabolic deficits, and chromosomal abnormalities have been described.*

**METHODS.** *Case report and review of the scientific literature.*

**RESULTS.** *The authors describe the ophthalmologic, pediatric, and neurologic evaluations and follow-up of a child with impaired horizontal saccades, jerky head movements, and delayed motor and speech development.*

**CONCLUSIONS.** *Congenital ocular motor apraxia is an uncommon disorder of ocular motility. Even so, ophthalmologists should be aware of the developmental delay and the other associated conditions, in order to grant the patients the multidisciplinary assistance they often require. (Eur J Ophthalmol 2008; 18: 282-4)*

**KEY WORDS.** *Congenital ocular motor apraxia, Developmental delay, Ocular motility disorder*

*Accepted: October 1, 2007*

## INTRODUCTION

Congenital ocular motor apraxia, described in 1952 by Professor David Cogan, is characterized by defective or absent voluntary and optically induced horizontal saccades and compensatory jerky head movements or thrusts to accomplish ocular refixation (1-3).

The most common initial sign is the inability to follow objects visually. The diagnosis is usually made between the fourth and eighth months of life, with the development of the head thrusts. Children with inadequate cephalic control may never develop the thrusts. When a visual stimulus is presented in the lateral peripheral field of view, an initial head thrust towards the stimulus and overshooting it occur. Both eyes move simultaneously in the opposite direction, responding to the active vestibulo-ocular system. While maintaining fixation, the head slowly moves back until the eyes are straight forward. The eyelids blink at the onset of the head movement to lower the gain of the vestibulo-ocular reflex and thus the amount of the head thrust. The dis-

ease is usually bilateral, but some authors have described unilateral and asymmetric cases (2-5).

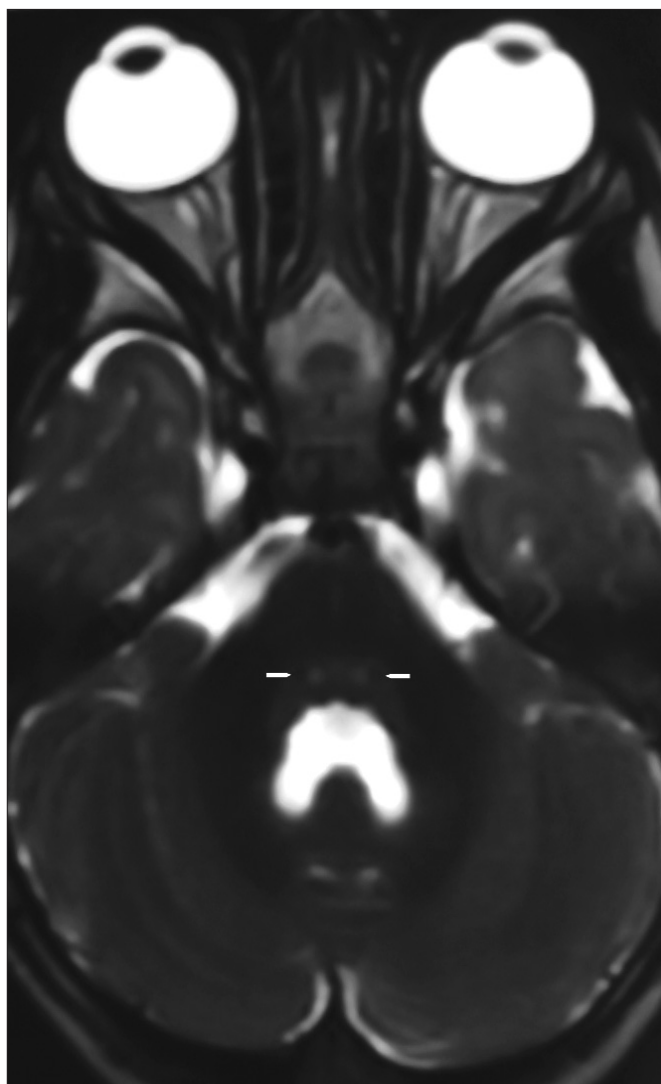
The vertical saccades, pursuit, and random eye movements are normal. However, cases of impairment of vertical saccadic movements have been described. The fast phases of optokinetic and vestibular evoked nystagmus are absent (2, 3).

With advancing age, the head thrusts become less prominent and tend to be replaced by blinking and to be seen only in tiredness and anxiety. Horizontal saccadic movements may emerge, albeit abnormal (2, 3).

Although congenital ocular motor apraxia has been described for more than 50 years, the etiology and physiopathology remain unresolved. The syndrome is related with impairment of the supranuclear control system of saccadic movements (2-5).

Both autosomal recessive and dominant inheritance patterns have been described (2-5).

Most affected patients present delayed psychomotor and speech development. Congenital ocular motor apraxia



**Fig. 1** - Axial T2-weighted scan shows bilateral and symmetric lesions at the pons (arrows).

may also be associated with Systemic Diseases – congenital hepatic fibrosis (COACH syndrome), neurofibromatosis – CNS Maldevelopment – cerebellar vermis hypoplasia or partial agenesis, dysgenesis of the *corpus callosum*, cerebellar hypoplasia, gray matter heterotopia, pachygyria – Metabolic Deficits – partial deficiency of NADH dehydrogenase, partial deficiency of pyruvate carboxylase – and Chromosomal Abnormalities – deletions in the nephronophthisis gene (NPHP 1), duplications of band p13 of chromosome 5 (2, 3).

The differential diagnosis includes visual acuity deficits, other ocular motor diseases, cephalic movement disorders, acquired ocular motor apraxia (e.g., posterior fossa lesions, bi-

lateral frontoparietal lesions), and syndromes in which ocular motor apraxia is an ocular sign-Joubert syndrome, ataxia-telangiectasia, ataxia-ocular motor apraxia type 1, ataxia-ocular motor apraxia type 2, and Gaucher disease type 3 (2, 3). Nystagmography, CNS magnetic resonance imaging (MRI), electrophysiologic studies, and metabolic study (lactate, pyruvate, ammonia, amino acids, organic acids, AFP, albumin, and immunoglobulin) assist in the diagnosis, the differential diagnosis, and the screening of associated diseases (2, 3).

### Case report

A 15-month-old boy was referred to us for evaluation of abnormal eye and head movements. Pregnancy and birth were normal. In the neonatal period he had neutropenia which required treatment with granulocyte colony stimulating factor in the neonatal intensive care unit. There was no known family history of relevant diseases. The parents were a young and non-consanguineous Senegalese couple.

With the head fixed, the patient was unable to make normal horizontal eye movements, but vertical movements were unaffected. With the head free and when a visual stimulus was presented in the lateral peripheral field of view, the child showed the sequence of movements characteristic of congenital ocular motor apraxia. The vestibulo-ocular reflex was normal. The fast phases of optokinetic nystagmus were absent. The remaining ophthalmologic evaluation was normal.

The pediatrics and neurologic evaluations were unremarkable, except for wide-based gait. The development evaluation with The Schedule of Growing Skills II showed normal gross motor skills, but a delay inferior to two standard deviations in the other items.

The CNS MRI identified bilateral and symmetric lesions at the pons, between the abducens and facial nerves nuclei and the medial longitudinal fasciculus (Fig. 1). The metabolic study was normal.

The patient has been submitted to a multidisciplinary follow-up. In our last evaluation (at 35 months old), the ocular motor apraxia was improved and the child demonstrated a better control of head thrusts. Pediatrics and neurologic evaluations were normal, but he maintained the psychomotor and speech delay.

Presently, the patient is attending a school with special education.

## DISCUSSION

Congenital ocular motor apraxia is an uncommon disorder of ocular motility. Many authors defend that this disease is infrequently unrecognized and little known. Only about 50 case reports have been published.

The etiology and physiopathology of the disease remain unknown. Although congenital ocular motor apraxia has been related with impairment of the supranuclear control system of saccadic movements, the site of the lesion has not been established. The neurologic control of horizontal saccades is complex and incompletely understood. The supranuclear center for horizontal saccadic movements is the paramedian pontine reticular formation (PPRF). The afferent connections to the PPRF are from the frontal eye fields, the vestibular nuclei, the superior colliculi, the cerebellum, and the perihypoglossal nuclei. Its major efferent projections are to the ipsilateral abducens nucleus. Secondary efferent projections are to the rostral interstitial nucleus of the medial longitudinal fasciculus (riMLF). Horizontal eye movements can also be affected by the posterior parietal lobe, the supplementary motor cortex, the thalamus, and the basal ganglia. Interneurons connect the ocular motor nuclei via the MLF and coordinate eye movements at a peripheral anatomic level. It may be assumed that a dysfunction of frontal eye fields (Brodmann area 8) and of the frontomesencephalic pathway is responsible for this disease (2-5). Samson et al advocated that congenital ocular motor apraxia only represents a maturation delay of the supranuclear control system of saccades (4). Harris et al suggested that congenital saccade initiation failure (c-SIF) is a more specific term for this disease, because this implicates a basic saccadic rather than an apraxic disorder (5).

The impairment of horizontal saccades and the head thrusts presented by our patient were typical of congenital ocular motor apraxia. The development evaluation showed an associated psychomotor and speech delay. However, the interpretation of this evaluation is not linear. The parents are from Senegal and the child is being brought up according to the Senegalese customs. The child had no contact with our social rules and language, or with other children. This background obviously also influences his psychomotor and speech development.

The clinical meaning and the relevance of the anatomic localization for the etiology of congenital ocular motor apraxia of the CNS lesions found in the MRI are uncertain. Description of such neuroradiologic findings was not de-

tected in the reviewed literature. None of the structural abnormalities of CNS characteristic of congenital ocular motor apraxia were identified in MRI.

The associated diseases and the developmental delay promote cognitive impairment, reading and learning difficulties (2, 3). Therefore, ophthalmologists should be aware of congenital ocular motor apraxia's associated conditions, in order to grant the patients the multidisciplinary assistance they often require, including physiotherapy, speech therapy, and special education.

*The authors report no financial support or propriety interest in this article.*

Reprint requests to:  
Sara Gonçalves Carrasquinho, MD  
Estrada da Luz  
n° 70, 4° direito  
1600-160 Lisboa, Portugal  
sgcarrasquinho@netcabo.pt

---

## REFERENCES

1. Cogan DG. A type of congenital ocular motor apraxia presenting jerky head movements. *Trans Am Acad Ophthalmol Otolaryngol* 1952; 56: 853-62.
2. Leigh JR, Daroff RB, Troost BT. Supranuclear disorders of eye movements. In: Tasman W, Jaeger E, eds. *Duane's Ophthalmology on CD-ROM*. Philadelphia, PA: Lippincott Williams & Wilkins, 2003.
3. Sargent MA, Poskitt KJ, Jan JE. Congenital ocular motor apraxia: imaging findings. *AJNR Am J Neuroradiol* 1997; 18: 1915-22.
4. Samson M, Mihout B, Proust B, Parain D. Congenital oculomotor apraxia. 2 cases with an electro-oculography study. *Rev Neurol (Paris)* 1983; 139: 515-8.
5. Harris C, Hodgkins P, Kriss A, et al. Familial congenital saccade initiation failure and isolated cerebellar vermis hypoplasia. *Dev Med Child Neurol* 1998; 40: 775-9.

Copyright of European Journal of Ophthalmology is the property of Wichtig Editore and its content may not be copied or emailed to multiple sites or posted to a listserv without the copyright holder's express written permission. However, users may print, download, or email articles for individual use.