

# TWO DIFFERENT OPTIONS IN THE TREATMENT OF PREMACULAR HEMORRHAGE SECONDARY TO MACROANEURYSM: About 2 clinical cases

Inês Coutinho, Mário Ramalho, Catarina Pedrosa, Cristina Vendrell, Filomena Silva, Manuela Bernardo  
Department of Ophthalmology, Hospital Prof. Doutor Fernando Fonseca, EPE, Portugal  
Director: Dr. António Melo



## INTRODUCTION

Premacular hemorrhage is one of the etiologies of sudden visual loss and may occur in a variety of disorders, including retinal artery macroaneurysm.

There isn't an ideal treatment and the choice must always be balanced against benefit/risk and patient's decision.

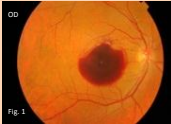Possible therapeutic options include observation, LASER posterior hyaloidotomy, vitrectomy or T-PA intravitreal injection.

## CLINICAL CASES

♂, 57 years old, with systemic hypertension

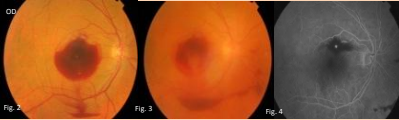
Sudden and painless loss of vision of the right eye (OD)

Visual acuity was light perception in OD and Fundoscopy revealed premacular hemorrhage (Fig.1)



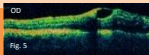
3 days after, a **posterior hyaloidotomy of the pre-retinal hemorrhage** (Fig. 2 = 3) was performed, with photodisruptive Nd: YAG LASER, to facilitate visual acuity recovery and minimize macular complications

Angiography was compatible with arterial macroaneurysm of a branch of the superotemporal arteriole (Fig.4)



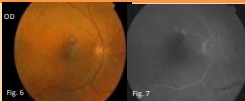
8 days after: VA OD=20/60  
2 months after: VA OD=20/30

OCT showed macular edema (Fig.5)



4 months after: VA OD 20/25

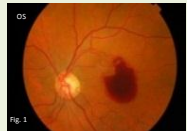Premacular hemorrhage was fully reabsorbed  
Macroaneurysm thrombosed (Fig.6., Fig.7)



♀, 56 years old

Sudden and painless loss of vision of the left eye (OS)

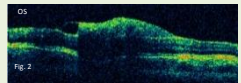
Visual acuity was finger counting to 1 meter in OS and Fundoscopy revealed premacular hemorrhage (Fig.1)



**No treatment was applied**

OCT revealed premacular hemorrhage (Fig.2)

Angiography was compatible with arterial macroaneurysm of a branch of the superotemporal arteriole

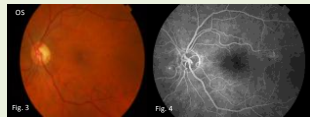


8 days after: VA OS= 20/400  
2 months after: VA OS=20/50

4 months after: VA OS=20/25

Premacular hemorrhage was fully reabsorbed  
Macroaneurysm thrombosed spontaneously

(Fig. 3, Fig.4)



## CONCLUSION

The premacular hemorrhage may cause a severe decrease in visual acuity, affecting the daily routine of patients and may also cause macular damage.

The first case was successfully treated with LASER posterior hyaloidotomy and no complications were reported. In the second no treatment was applied.

The major advantage of LASER posterior hyaloidotomy was a faster visual recovery although the long term results were similar in both cases. Another advantage is visualization of subjacent retina that allows macroaneurysm photocoagulation if necessary.