



- The role of echocardiography in sports cardiology

**Right ventricular adaptation
in endurance athletes.**

António Freitas

Cardiology Department - Fernando Fonseca Hospital – Lisbon

Sports Medicine Centre - Lisbon

No conflict of interest

Right ventricular adaptation in endurance athletes.

- **Summary:**

- **Cardiac adaptation to endurance training**
 - **General overview**
 - **The right ventricle specificity**
 - **Normal patterns/upper limits of normal**
- **May prolonged exercise be harmful for the right ventricle ?**
- **How can we distinguish the normal adaptation from pathology (ARVC)**

Type of Exercise: Hemodynamic Effects

Dynamic / Isotonic Exercise

- Submaximal / prolonged / repetitive
- Large muscle group
- Aerobic metabolism
- Increase CO / low TPR
- Volume overload

Static / Isometric Exercise

- Rapid / intense / short duration
- Anaerobic metabolism
- Increase HR / TPR / SBP / DBP
- Pressure overload

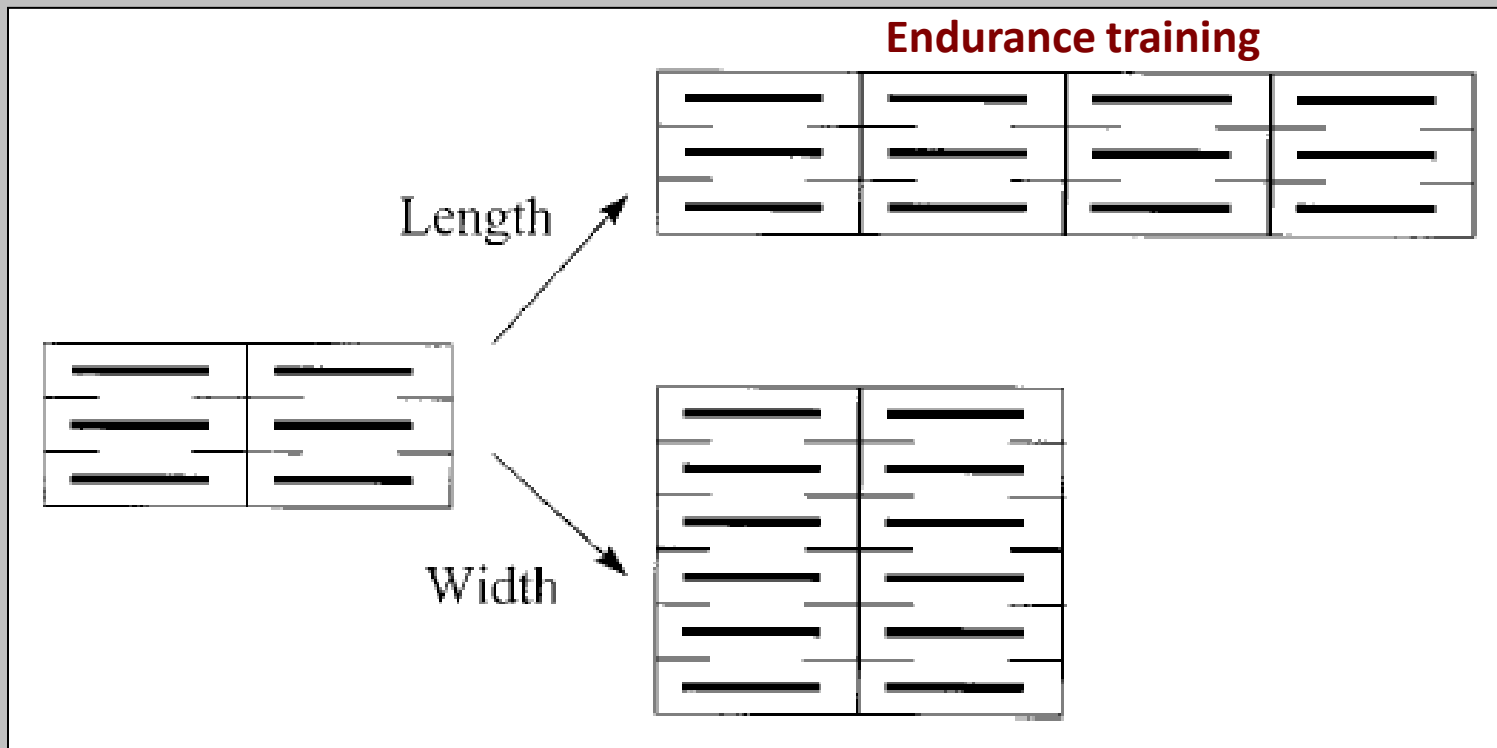
Cardiovascular Adaptation to Exercise Training

Conditioning factors

- **Type of exercise**
- **Intensity**
- **Frequency**
- **Duration**
- **Genetic**
- **Gender**
- **Age**
- **Ethnicity**

Form follows function:

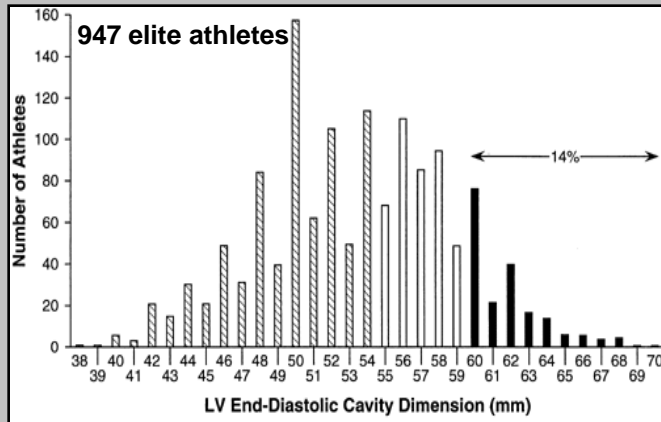
- *how muscle shape is regulated by work?*



B. Russell et al - *J Appl Physiol* 88:1127-1132, 2000.

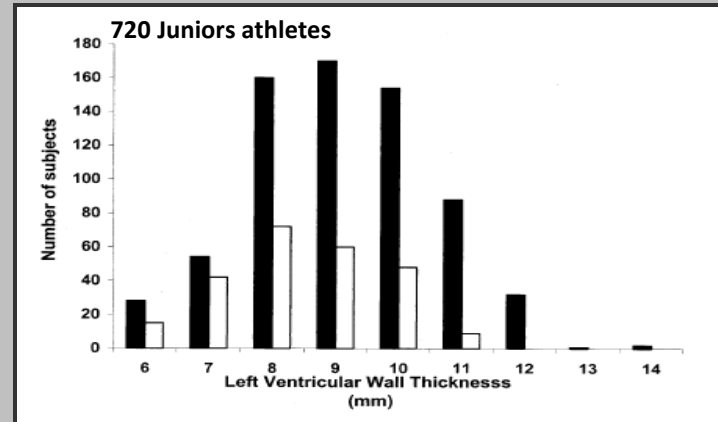
Left ventricle remodeling and adaptation to exercise training in athletes

End Diastolic Dimension and Wall Thickness in Athletes



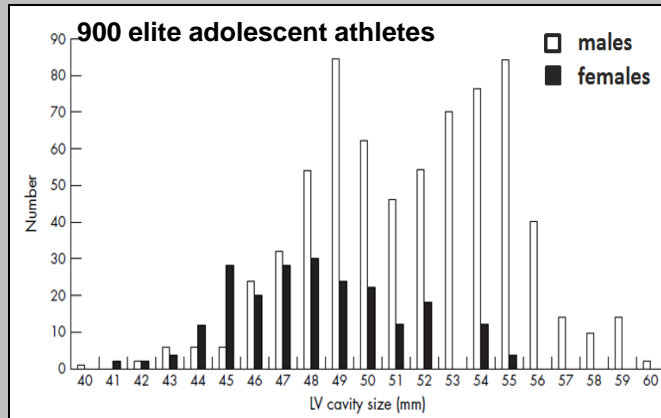
A. Pelliccia et al. NEJM 1991

Physiologic Limits of LV Hypertrophy in Elite Junior Athletes:



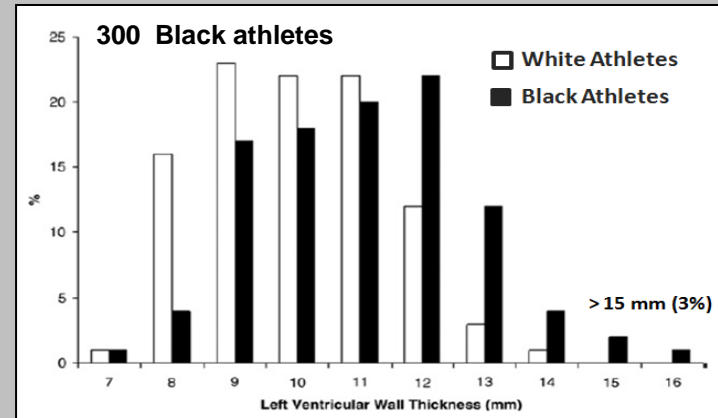
Sharma S et al. JACC 2002

Physiological upper limits of LV cavity size in highly trained adolescent athletes – males vs females



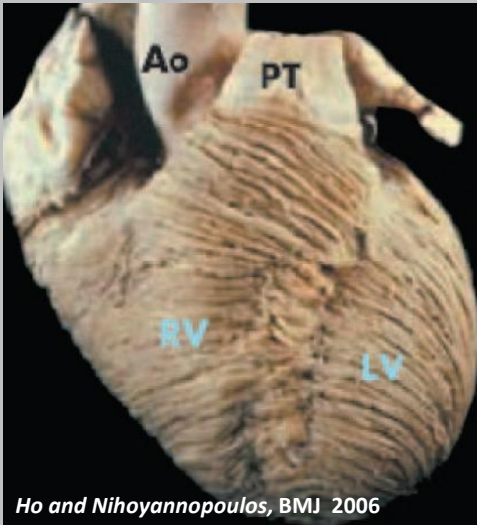
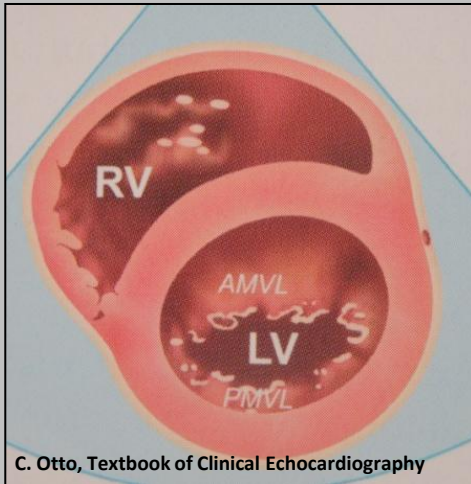
Makan J et al. Heart 2005

Ethnic Differences in LV Remodeling in Highly-Trained Athletes



Basavarajaiah S et al. JACC 2008

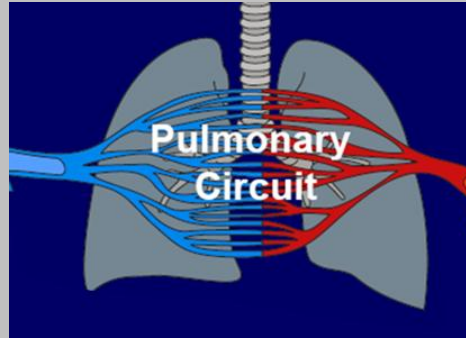
Normal anatomy and physiology of the RV



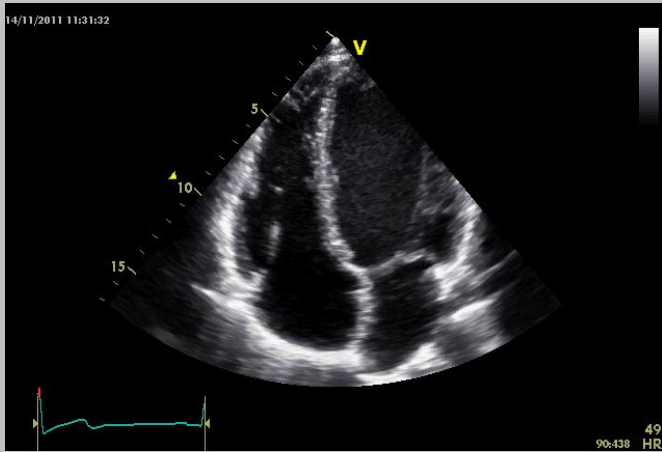
- Complex geometry, crescent-shaped
- Heavily trabeculated and poor endocardial definition
- Ventricular interdependency
- Separate inflow and outflow
- Low resistance pulmonary circulation
- More dependent of preload and afterload

Cardiac output ↑↑↑

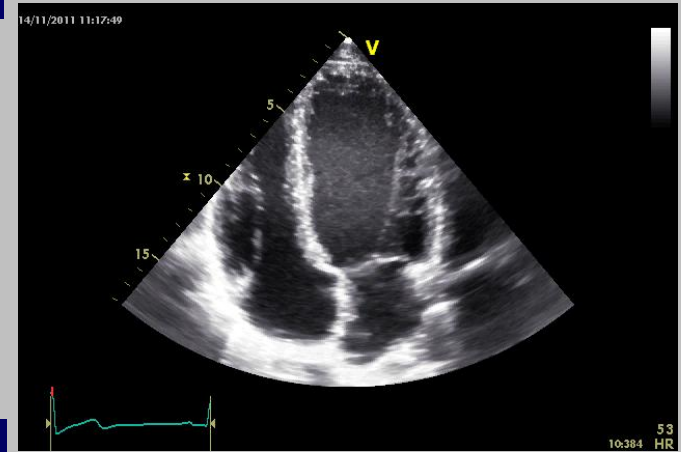
Pulmonary resistance ↓



NO synthetase
Metalloproteinases
↓ pulmonary vascular reserve
Other vasodilators factors



During exercise



Cardiac output ↑↑↑

Systemic resistance ↓↓↓

How to assess RV morphology and function?

- **Echocardiography**
- **CMR imaging**
- **CT imaging**
- **Radionuclide angiography**
- **RV catheterization**

How to study the RV adaptation to exercise training in athletes?

GUIDELINES AND STANDARDS

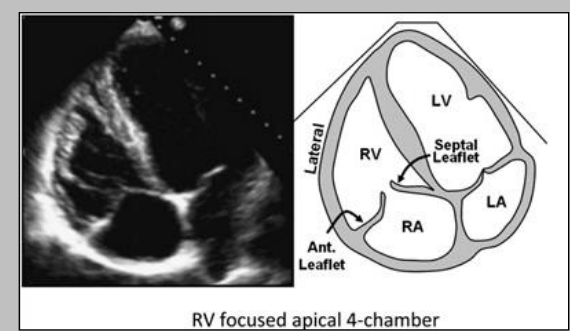
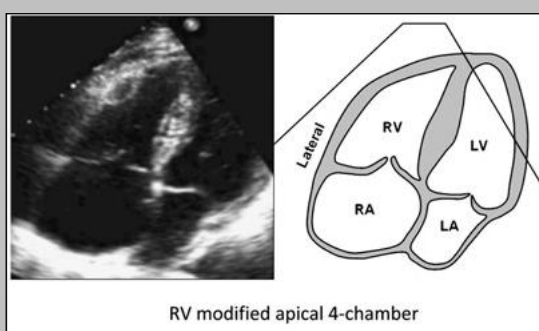
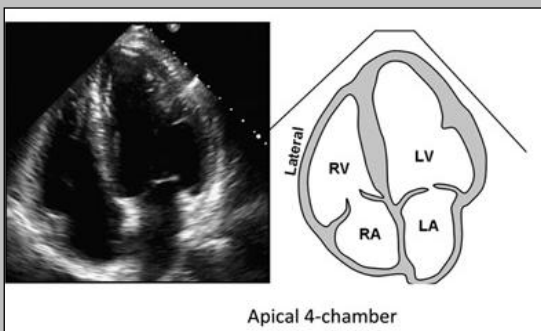
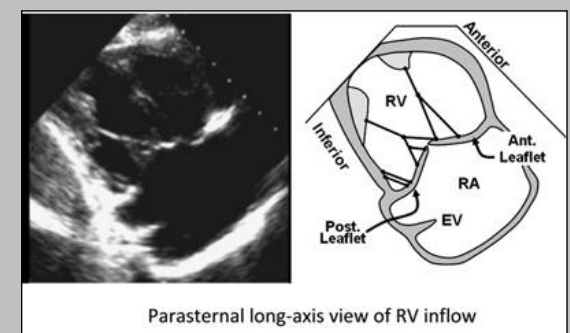
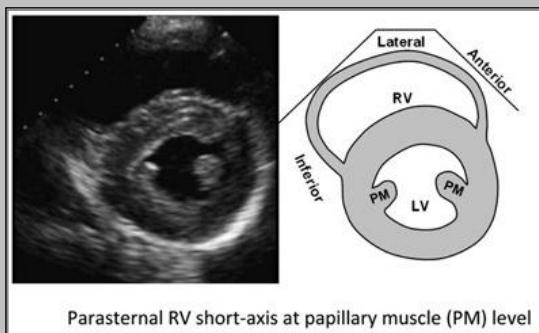
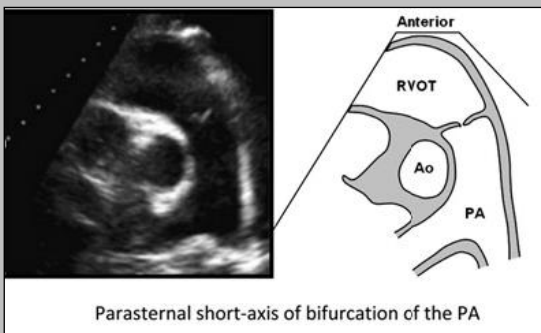
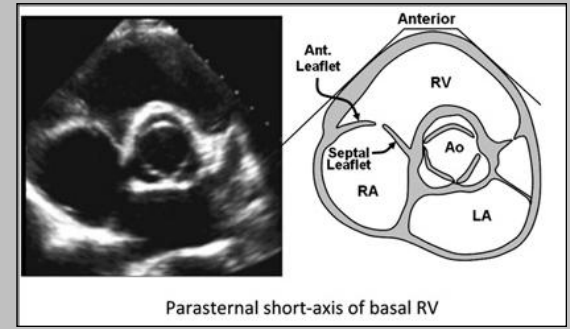
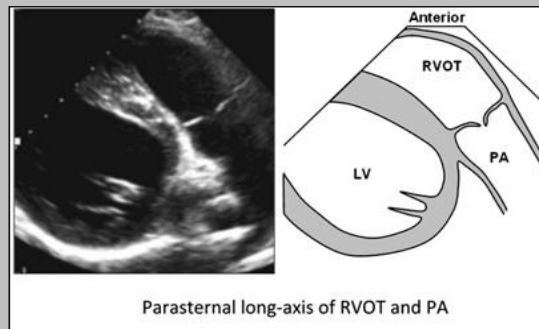
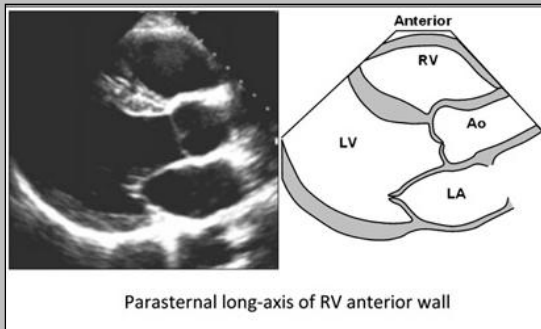
Guidelines for the Echocardiographic Assessment of the Right Heart in Adults: A Report from the American Society of Echocardiography

Endorsed by the European Association of Echocardiography, a registered branch of the European Society of Cardiology, and the Canadian Society of Echocardiography

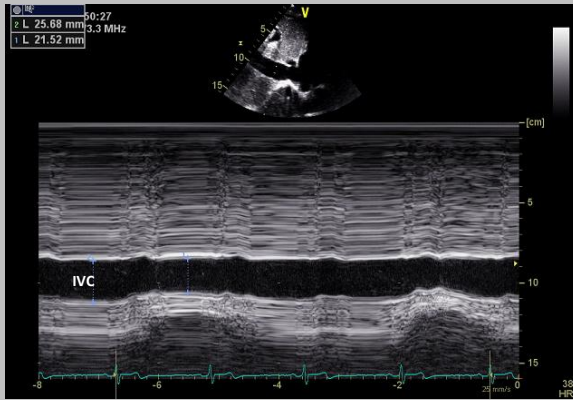
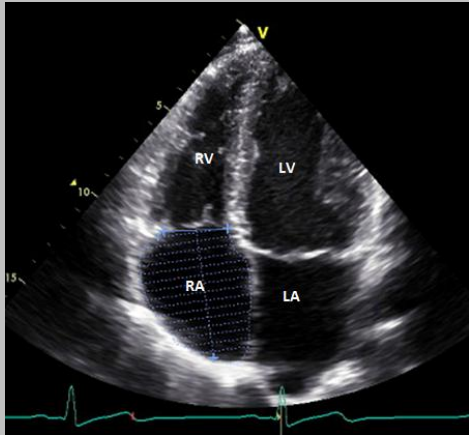
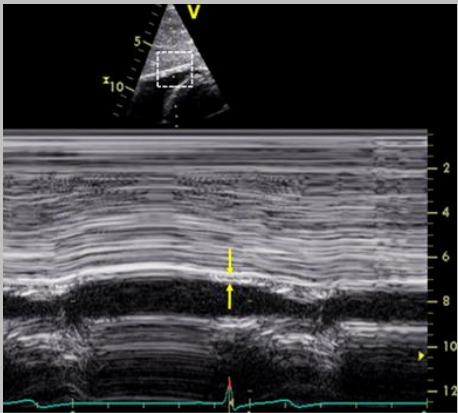
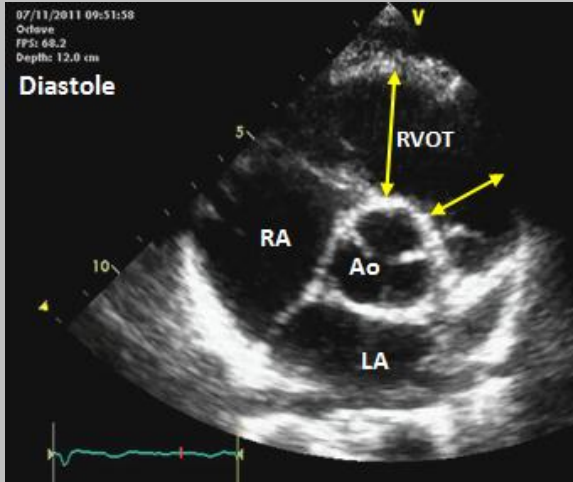
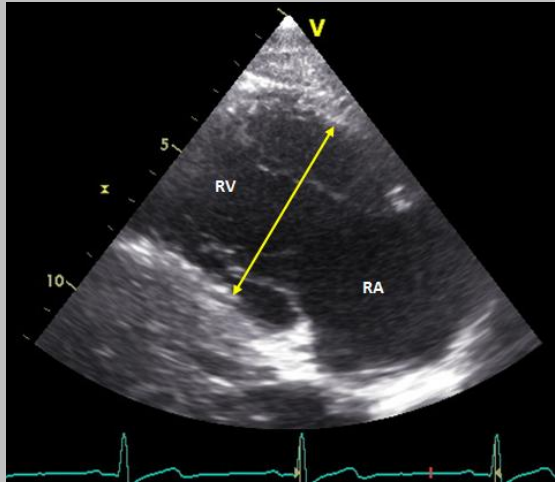
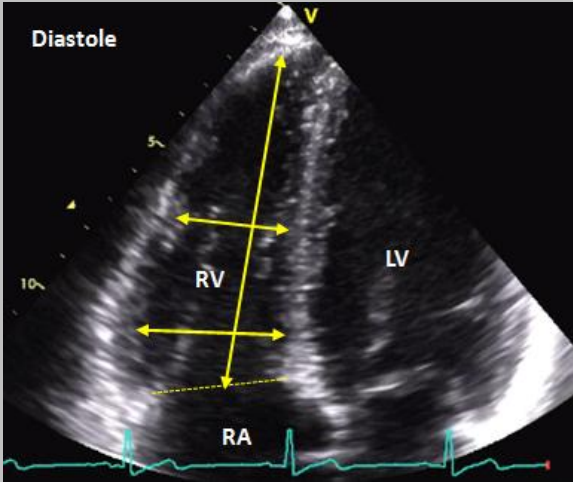
Lawrence G. Rudski, MD, FASE, Chair, Wyman W. Lai, MD, MPH, FASE, Jonathan Afilalo, MD, Msc, Lanqi Hua, RDCS, FASE, Mark D. Handschumacher, BSc, Krishnaswamy Chandrasekaran, MD, FASE, Scott D. Solomon, MD, Eric K. Louie, MD, and Nelson B. Schiller, MD, *Montreal, Quebec, Canada; New York, New York; Boston, Massachusetts; Phoenix, Arizona; London, United Kingdom; San Francisco, California*

(J Am Soc Echocardiogr 2010;23:685-713.)

Guidelines for the Echocardiographic Assessment of the Right Heart in Adults: - A Report from the American Society of Echocardiography



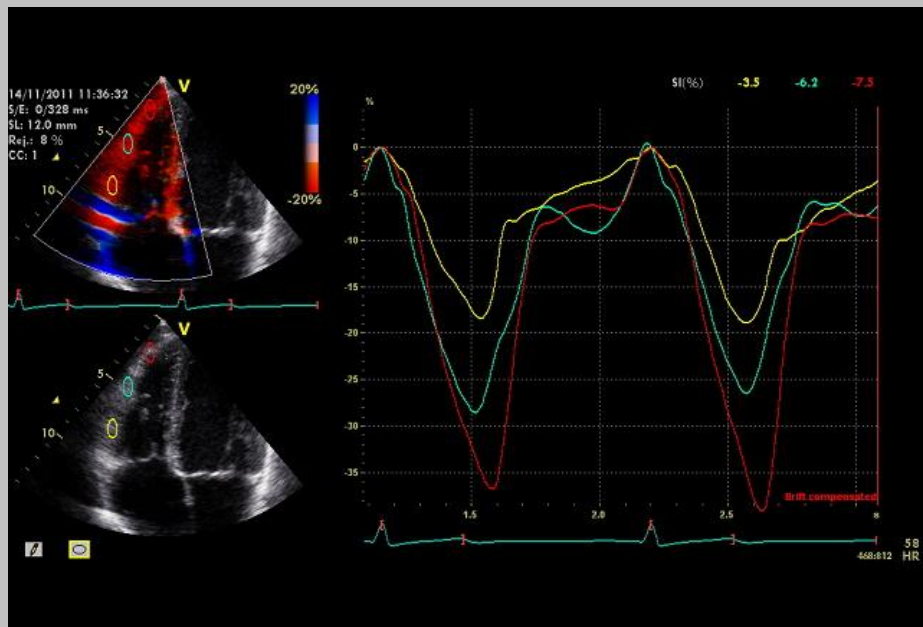
Echo - RV morphology



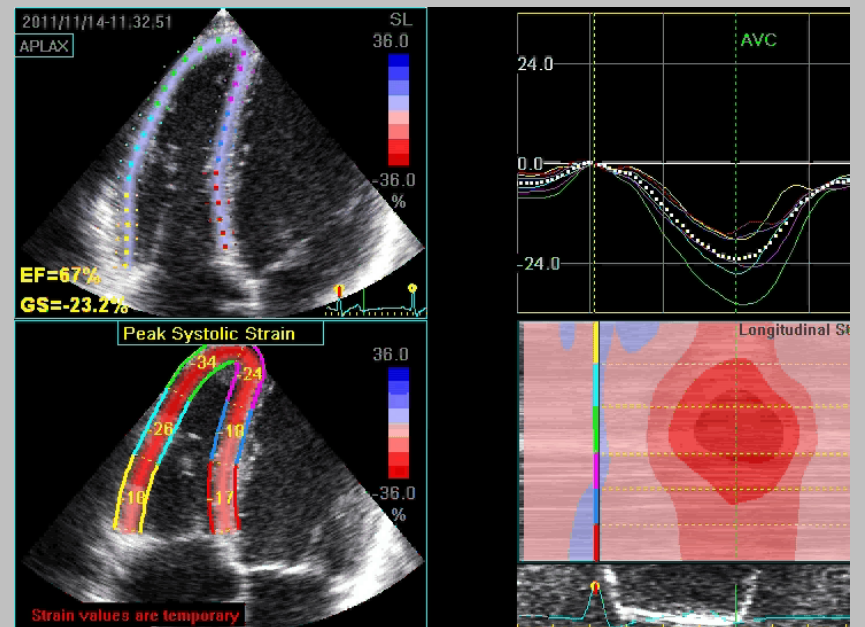
Assessing - RV morphology and function - *New Echo Modalities*

Myocardial Deformation Imaging

TDI derived Strain



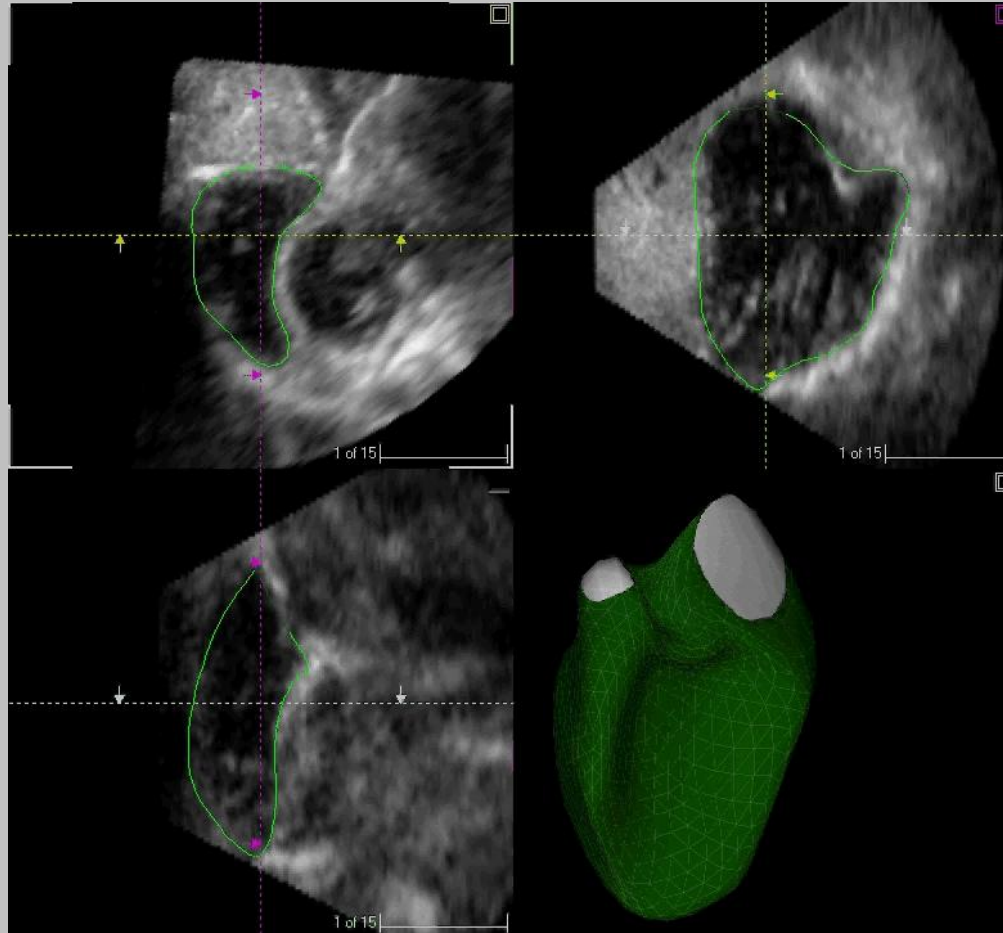
2D Strain (Speckle Tracking derived)



Assessing RV morphology and function

- *New Echo Modalities*

- 3D Echo (RV volumes and EF)



Courtesy of TomTec Imaging Systems

Right ventricular adaptation in endurance athletes.

. . . what about the Right Ventricle?

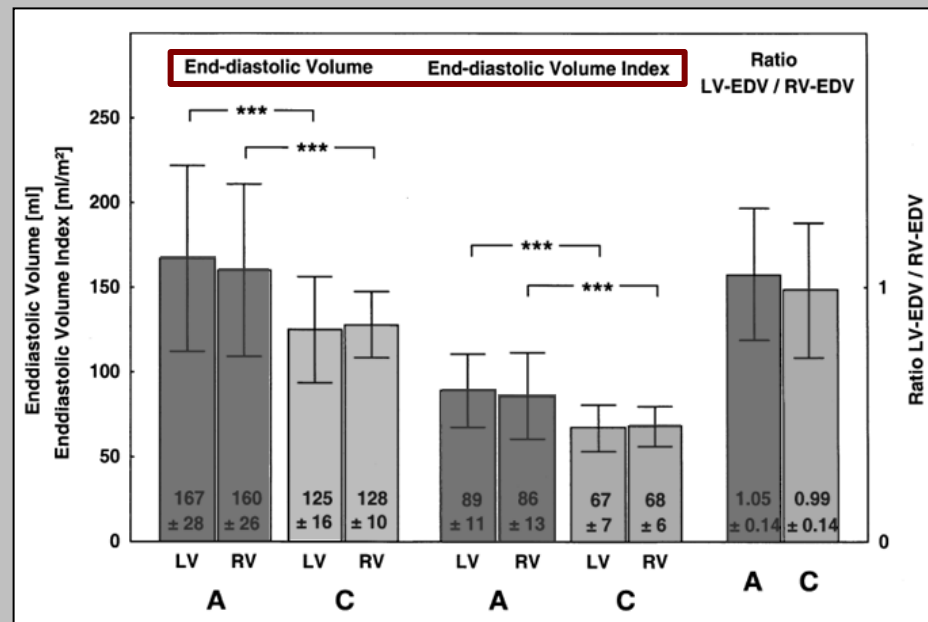
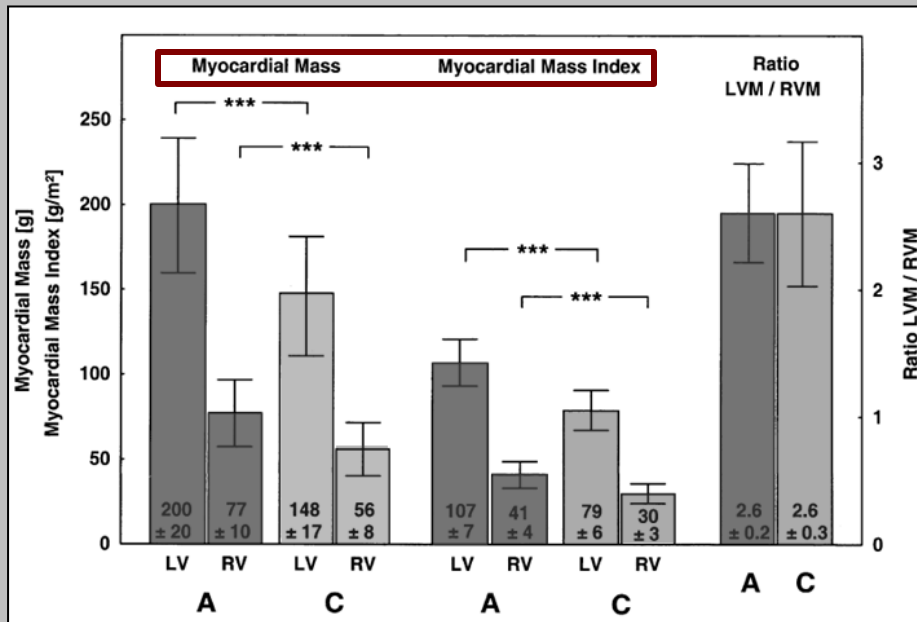
Symmetric cardiac enlargement in highly trained endurance athletes: a two-dimensional echocardiographic study.

(12 Athletes) *Hauser A et al. Am Heart J 1985*

Echocardiographic right and left ventricular measurements in male elite endurance athletes **(127 athletes)**

. . cardiac enlargement occurs symmetrically in both right and left cavities. *Henriksen et al. Eur Heart J 1996*

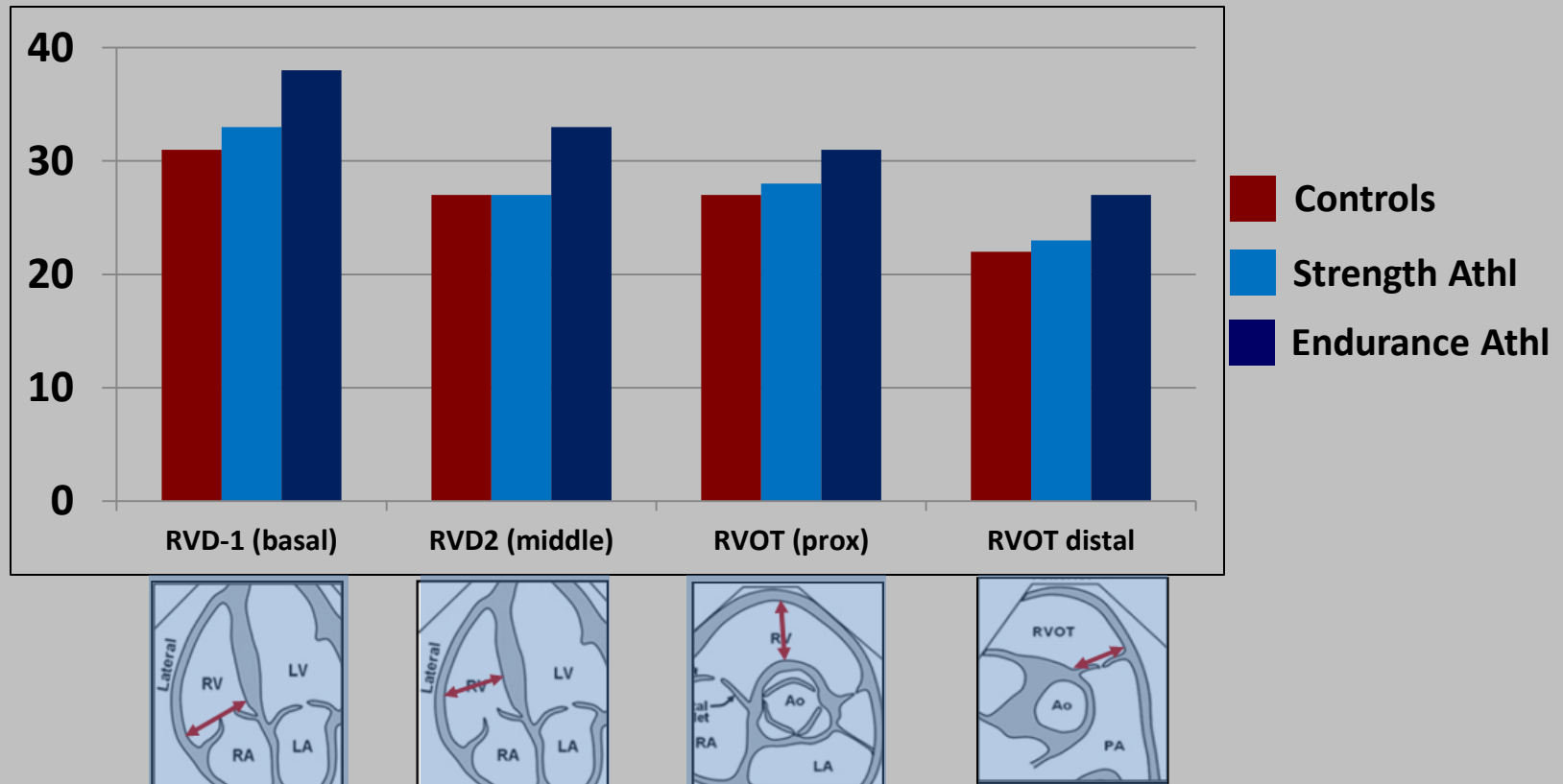
Athlete's Heart - Right and Left Ventricular Mass and Function in Male Endurance Athletes and Untrained Individuals Determined by Magnetic Resonance Imaging



J Scharhag et al. J Am Coll Cardiol 2002

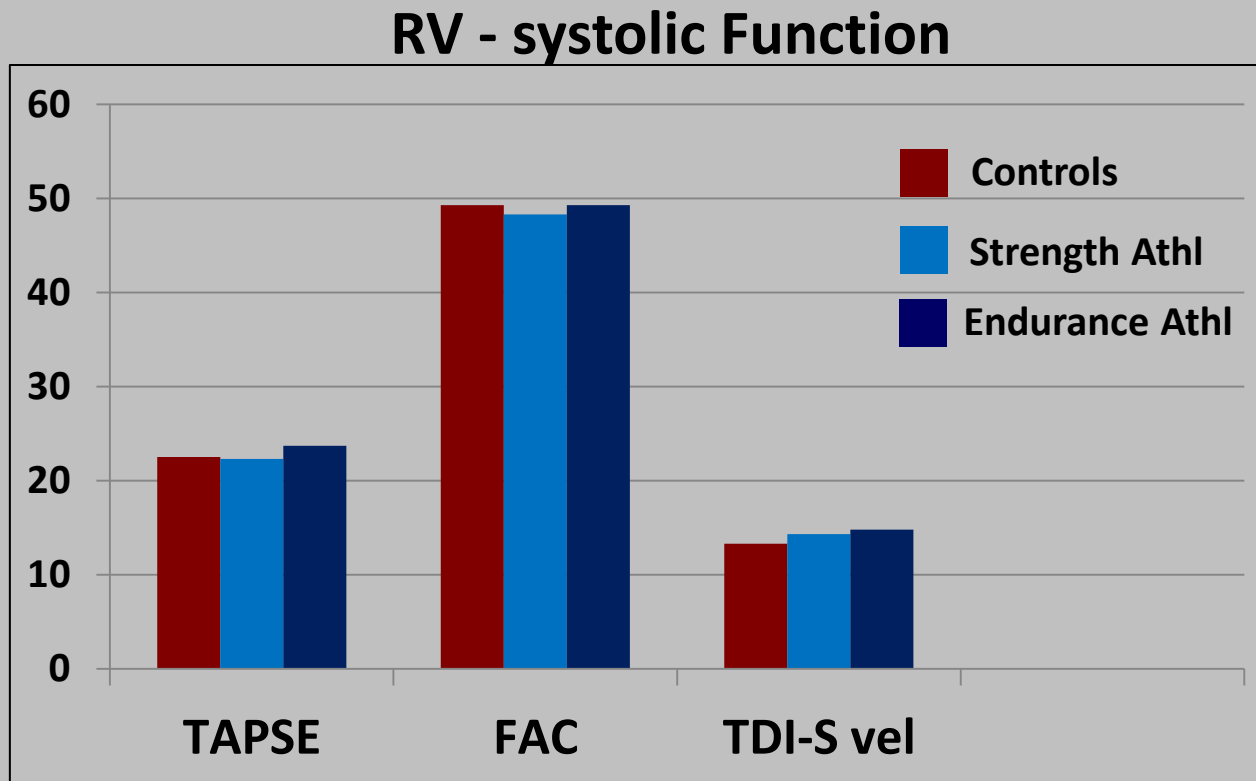
Range of right heart measurements in top-level athletes: The training impact

- 650 top-level athletes (395 Endurance and 255 Strength trained)
- Echo evaluation

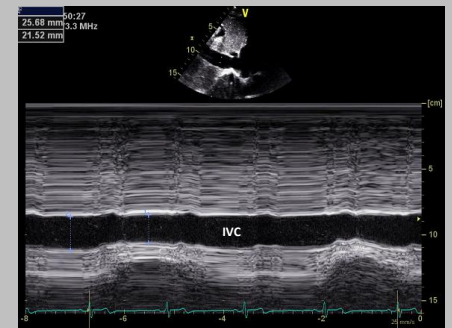
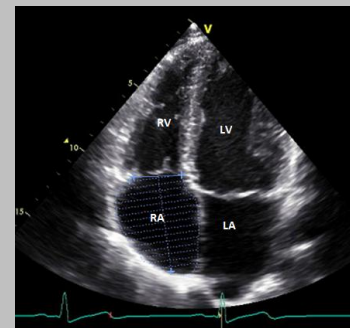
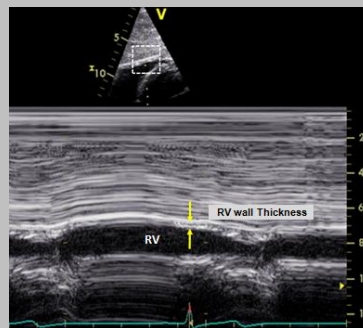
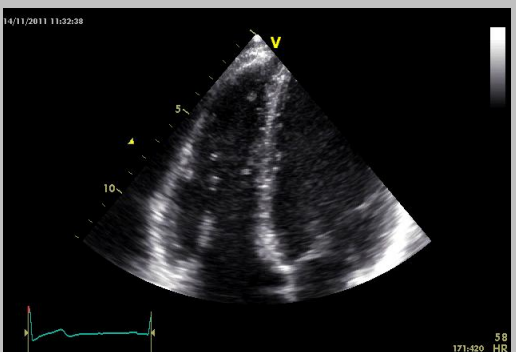
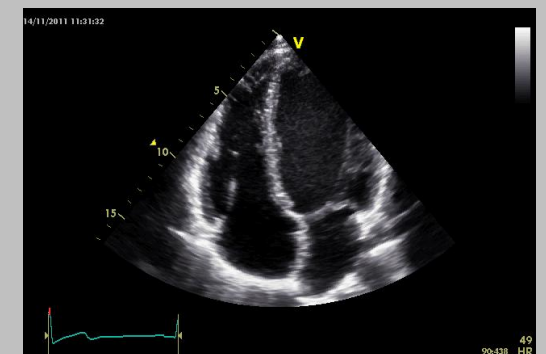
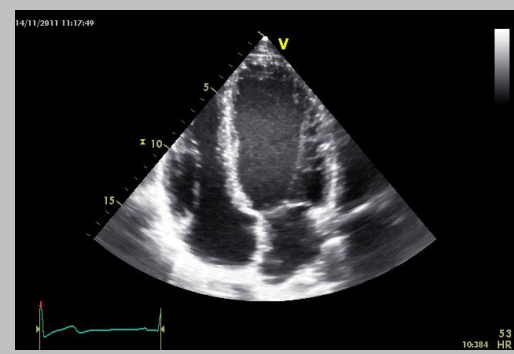
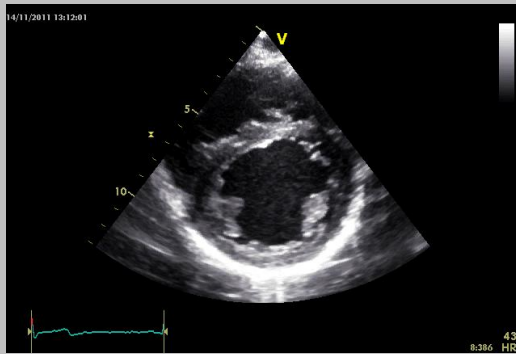
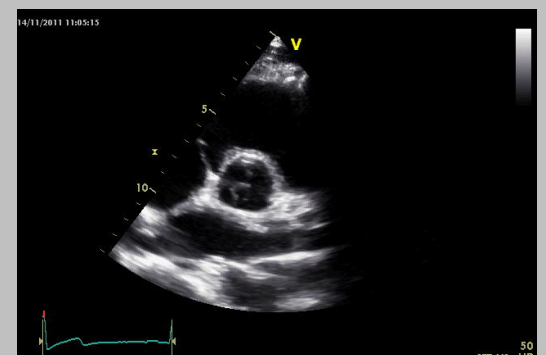
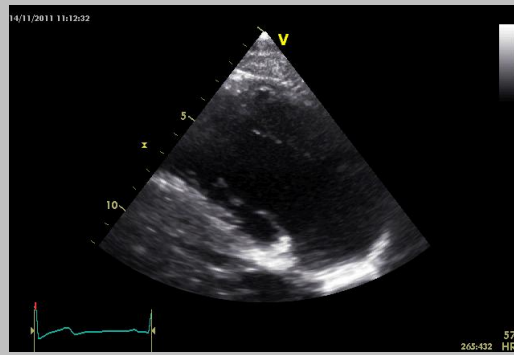
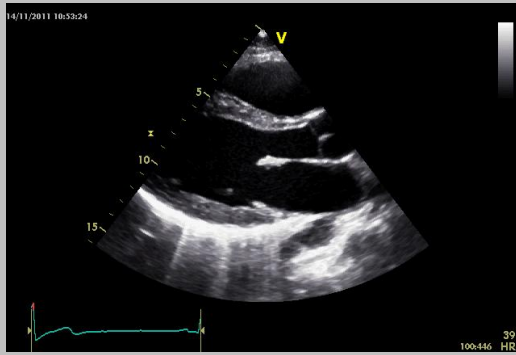


Range of right heart measurements in top-level athletes: The training impact

- 650 top-level athletes (395 Endurance and 255 Strength trained)



The right heart of endurance athlete - morphology



Right ventricular adaptation in endurance athletes.

- **May prolonged exercise damage the RV ?**

- **Exercise induced cTn elevation**
- **Transient post exercise RV dysfunction**
- **Chronic RV abnormalities presenting with malignant arrhythmias**



Troponin release following endurance exercise: is inflammation the cause? A cardiovascular magnetic resonance study

17 male athletes; **CMR** - 24 hrs pre and 6 hrs post-marathon.

cTnI and NTproBNP -> 24 hrs pre, immediately after, and 6 hrs post-marathon.

Conclusion: Exercise induced cardiac biomarker release is not associated with any functional changes by CMR or any detectable myocardial inflammation or fibrosis.

Right ventricular adaptation in endurance athletes.

- How can we distinguish the RV normal adaptation from pathology

Diagnosis of ACM / ARVC

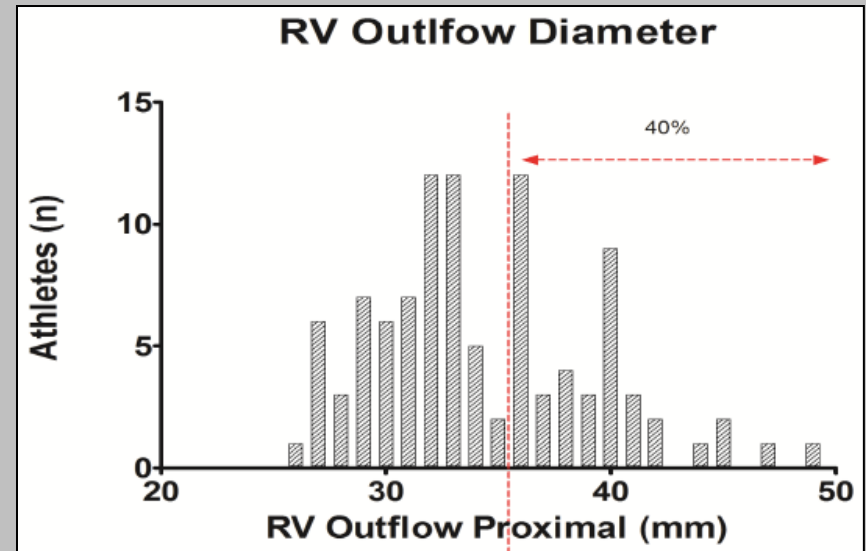
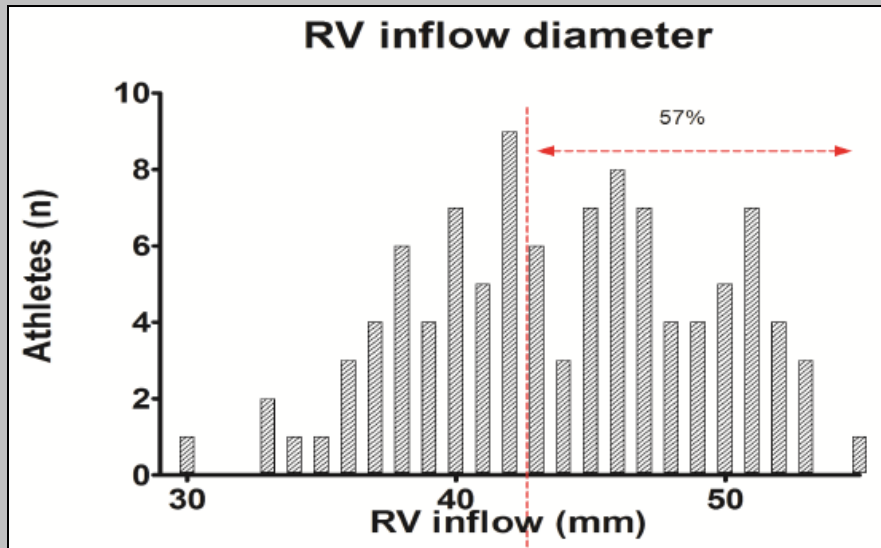
Revised Task Force Criteria - Marcus F, McKenna W et al Circ – 2010

- I. Global or regional dysfunction and structural alterations
- II. Tissue characterization of wall
- III. Repolarisation abnormalities
- IV. Depolarization/conduction abnormalities
- V. Arrhythmias
- VI. Family history

Diagnosis ARVC - Revised TFC 2010

Diagnosis	Criteria	Score
Definite	<ul style="list-style-type: none">• 2 major• 1 major + 2 minor• 4 minor	4
Borderline	<ul style="list-style-type: none">• 1 major + 1 minor• 3 minor	3
Possible	<ul style="list-style-type: none">• 1 major• 2 minor	2

The right ventricle of the endurance athlete: the relationship between morphology and deformation



Oxborough D et al. *Heart* 2011

ARVC - Revised Task Force Criteria 2010

I. Global or regional dysfunction and structural alterations

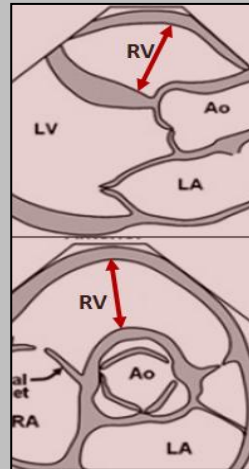
By 2D echo: Regional RV akinesia, dyskinesia or aneurysm

• and 1 of the following (end diastole):

major

≥ 32 mm
(≥ 19 mm/m²)

≥ 36 mm
(≥ 21 mm/m²)



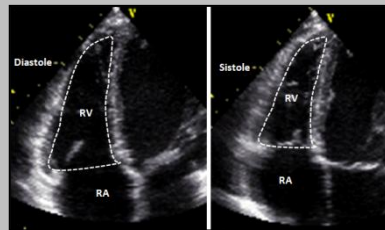
minor

≥ 29 to < 32 mm
(≥ 16 to < 19 mm/m²)

≥ 32 to < 36 mm
(≥ 18 to < 21 mm/m²)

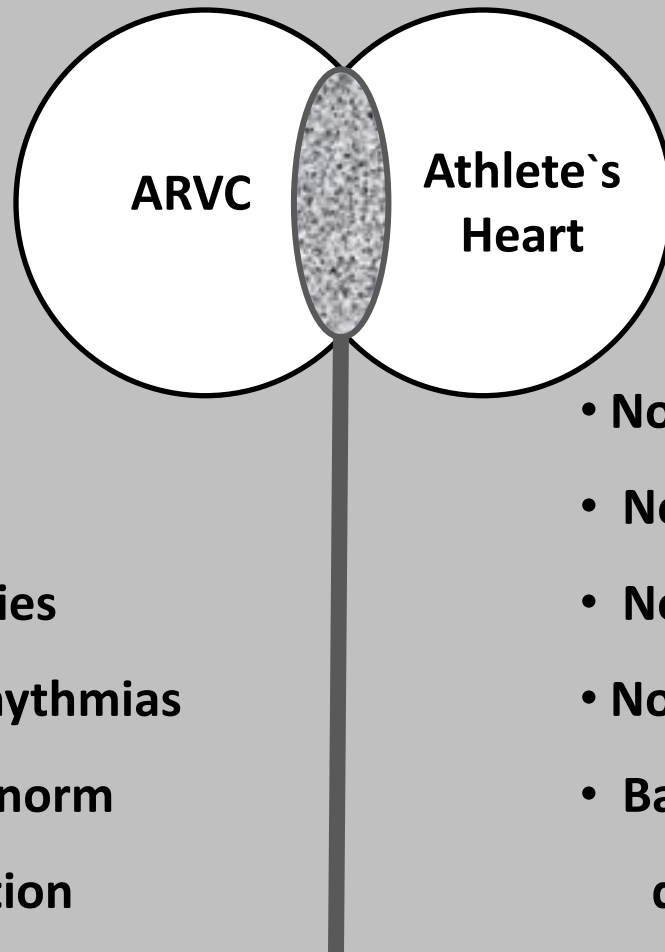
OR fractional area change

FAC < 33%



FAC > 33% to $\leq 40\%$

ARVC or Physiological RV Adaptation ?



- Symptoms
- Family Hx
- ECG abnormalities
- Ventricular Arrhythmias
- Wall motion Abnorm
or RV dysfunction

- No Symptoms
- Negative family Hx
- Normal ECG
- No WMA or RV dysfunction
- Balanced Biventricular
dilatation

How to distinguish ARVC from RV adaptation to exercise training?

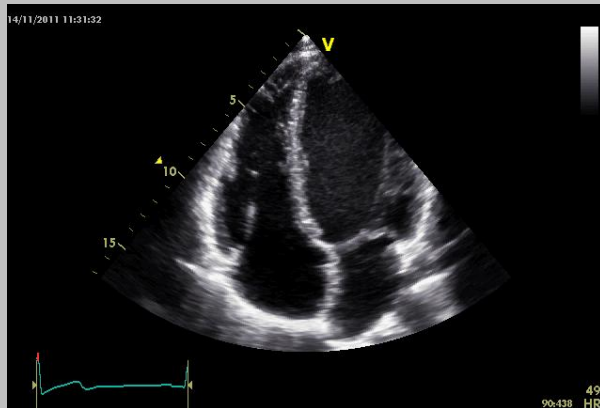
- Clinical evaluation
- ECG and SAECG
- Holter monitoring
- Exercise stress test
- Echocardiography

- Cardiac Magnetic Resonance
- Angiography, EPS, EMB, Genetic testing, etc

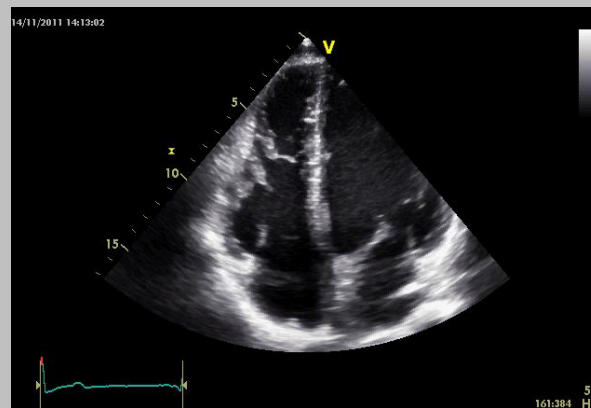
Right ventricular adaptation in endurance athletes.

- How can we distinguish the normal adaptation from pathology

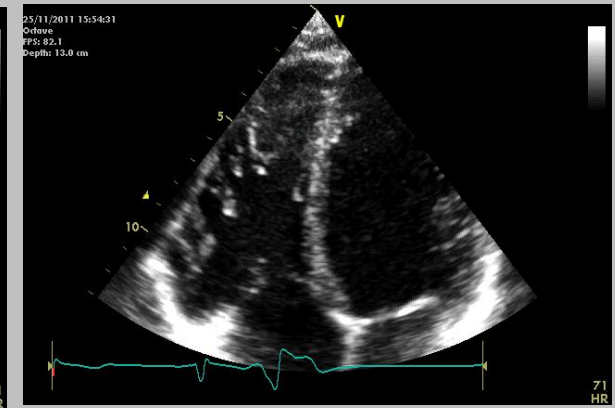
Male, 22 Y, Triathlon (< 2 h)
(High level competition)



Male, 22 Y, Triathlon (< 2 h)
(High level competition)



Male, 17 Y, soccer
(Recreational)



RV adaptation in endurance athletes.

Conclusions:

- Increase RV cavity, inflow and outflow tract by Echo. Normal RV function at rest
- Increase RV mass and volumes by MRI, with ratio LV/RV maintained
- Most of the studies no correlation between transient RV dysfunction and cTn release
- No persistent myocardial dysfunction, inflammation or fibrosis by LE-MRI

RV adaptation in endurance athletes.

Conclusions:

- Physiologic RV adaptation may induce RV dilatation, but no WMA or RV dysfunction
- *Gray-Zone* Athletes' heart vs ARVC:
 - Clinical evaluation, ECG, SAECG, Echo . . MRI . . and Genetic testing, EPS, EMB

Thank you for your attention!