

Comparison of Macular Thickness and Volume in Amblyopic Children using Time Domain Optical Coherence Tomography

Filipe Silva¹, Samuel Alves¹, Susana Pina¹, Ana Rita Azevedo¹, Peter Pêgo¹, Maria João Santos¹, Ricardo São João²

¹Serviço de Oftalmologia do Hospital Prof. Dr. Fernando Fonseca EPE

²Instituto Politécnico de Santarém

RESUMO

Objectivo: Alterações corticais e do corpo geniculado externo estão bem documentadas na ambliopia mas o envolvimento retiniano é controverso. Pretende-se comparar o volume e espessura maculares entre o olho ambliope e o olho adelfo, em crianças com ambliopia unilateral por anisometropia ou estrabismo, utilizando a tomografia de coerência óptica.

Material e métodos: Crianças até aos 18 anos, com diagnóstico de ambliopia unilateral, foram examinadas por meio de Stratus OCT, para obtenção de volume e espessura maculares. A análise estatística foi feita com recurso ao teste não-paramétrico dos postos de Wilcoxon para amostras emparelhadas.

Resultados: Foram estudadas 19 crianças, 15 das quais com estrabismo e 4 com anisometropia. A espessura foveal mínima foi significativamente maior no olho ambliope. Verificou-se uma redução estatisticamente significativa da espessura da mácula no olho ambliope nas áreas nasal interna, inferior interna e inferior externa; o volume e espessura maculares foram também inferiores noutras áreas maculares do olho ambliope, sem significado estatístico.

Conclusão: Parece haver diferença na espessura macular entre o olho ambliope e o olho adelfo, em crianças com ambliopia por estrabismo ou anisometropia, pelo menos nalgumas áreas maculares. Os nossos resultados estão de acordo com trabalhos já publicados, apesar de serem refutados por outros, reflectindo as diferentes condições experimentais em que foram realizados.

Palavras-chave

Ambliopia, estrabismo, anisometropia, tomografia de coerência óptica.

ABSTRACT

Purpose: Cortical and lateral geniculate changes are well documented in amblyopia but retinal involvement is controversial. Our aim was to compare macular volume and thickness between

the sound and the amblyopic eye, in children with unilateral amblyopia due to anisometropia or strabismus, using optical coherence tomography.

Materials and Methods: Amblyopic children up to the age of 18 were examined with Stratus OCT3, assessing macular volume and thickness. Statistical analysis was done using the Wilcoxon signed rank test and a level of significance of 5% was chosen.

Results: 19 amblyopic patients were studied, 15 with strabismus and 4 with anisometropia. The foveal minimum thickness was significantly greater in the amblyopic eye; by contrast, significantly reduced thickness was found in the inner nasal, inner inferior and outer inferior macular areas of the amblyopic eye. Macular volume and retinal thickness in the other macular areas were reduced in amblyopic eyes but this was not significant.

Conclusions: There seems to be a difference in macular thickness between both eyes in patients with unilateral amblyopia due to strabismus or anisometropia, at least in some areas. Our results are according to some studies performed so far, although others contradict these results, reflecting the different experimental settings used.

Key-words

Amblyopia, strabismus, anisometropia, optical coherence tomography.

INTRODUCTION

Amblyopia may be defined as a reduced best corrected visual acuity in one or both eyes, due to abnormal visual experience during the critical period of visual development.

It is the most frequent cause of unilateral poor visual acuity in children and young adults, with an estimated incidence of 1.6-3.6%¹, although its incidence could be higher in medical underserved populations². Although it usually develops during the first 2-3 years of postnatal period, amblyopia can be developed up to the age of 9.

This condition is secondary to visual deprivation or abnormal ocular interaction and is usually divided into three sub-types: strabismic, anisotropic/ametropic and form deprivation (cataract, ptosis, nystagmus); furthermore, these can co-exist.

Functional changes are well documented in amblyopia, including loss of visual acuity and contrast sensitivity³. As for structural changes, visual cortex and lateral geniculate nucleus are known to be affected in amblyopia but retinal involvement is still a controversial issue, with different studies showing conflicting results.

Optical coherence tomography (OCT) is a noninvasive technique, allowing high resolution, cross-sectional tomographic imaging of the retina and optic nerve. Our aim was to compare macular thickness and volume between the normal and the amblyopic eye, in children with unilateral amblyopia due to strabismus or anisometropia, using Stratus OCT3, based on time domain (TD) detection technology.

PATIENTS AND METHODS

This prospective study was performed according to the tenets of the Declaration of Helsinki for research in human subjects. Written informed consent was obtained from the parents of all enrolled children.

Children up to the age of 18, presenting with unilateral amblyopia, were considered eligible for this study. Amblyopia was defined as a best corrected visual acuity (BCVA) difference of at least 2 lines; causes for amblyopia included either strabismus or anisometropia, defined as a cycloplegic spherical equivalent difference greater than 2 diopters between both eyes. Clinical examination included BCVA at 6 meters with Snellen chart (or tumbling "E" when needed); ocular motility and alignment evaluation, including cover testing at near and distance; cycloplegic refraction with automated refractor RM8900 (Topcon, Tokyo, Japan); anterior segment examination; intra-ocular pressure measurement and funduscopy. Exclusion criteria included ocular disease, previous ocular surgery, cycloplegic refractive error higher than 5 diopters (either myopia or hyperopia), strabismic plus anisotropic amblyopia, neurological disease, nystagmus, OCT signal less than 5 and uncooperative children unable to keep fixation.

Patients were dilated with cyclopentolate 1%, 1 drop every 5 minutes for 15 minutes. 20 minutes later, after dilation was complete, OCT was performed using the Stratus OCT3 (Carl Zeiss-Humphrey-Meditec, Dublin, California, USA). The software used was 4.0.2. Images were obtained

with the Fast Macular Thickness Map, which consists of six consecutive 6 mm radial line scans centered on the macula. Macular scans were evaluated with *Retinal Thickness/Volume Tabular* program, displaying the results in three concentric circles, as shown in figure 1. The central ring was the foveal region, measuring 1.00 mm in diameter; the inner and outer rings were each divided in 4 quadrants, having 3 and 6 mm in diameter, respectively. An average retinal thickness and volume were reported for each of the nine regions, as well as the foveal minimum thickness and total macular volume. Each OCT was performed by the same operator and only the images centred on the fovea were accepted.

For the statistical analysis we used the non-parametric Wilcoxon signed rank test for related samples, given the fact that our data distribution was not normal and the

sample size was small. Differences of macular volume and thickness were considered significant ($\alpha=0.05$) if the smallest sum of the ranks of the same sign were lesser or equal than the critical values present in the Wilcoxon table ^{4,5}.

RESULTS

19 patients were included in this study, 13 of which were female (68.4%) and 6 were male. Mean age was 8.05 years, ranging from 4 to 14 years. Strabismic amblyopia was present in 15 patients (78.9%) and anisometric amblyopia in 4 patients. 10 cases involved the left eye (52.6%).

Among the studied children, the foveal minimum thickness was significantly greater in the amblyopic eye; by contrast, significantly reduced thickness was found in the

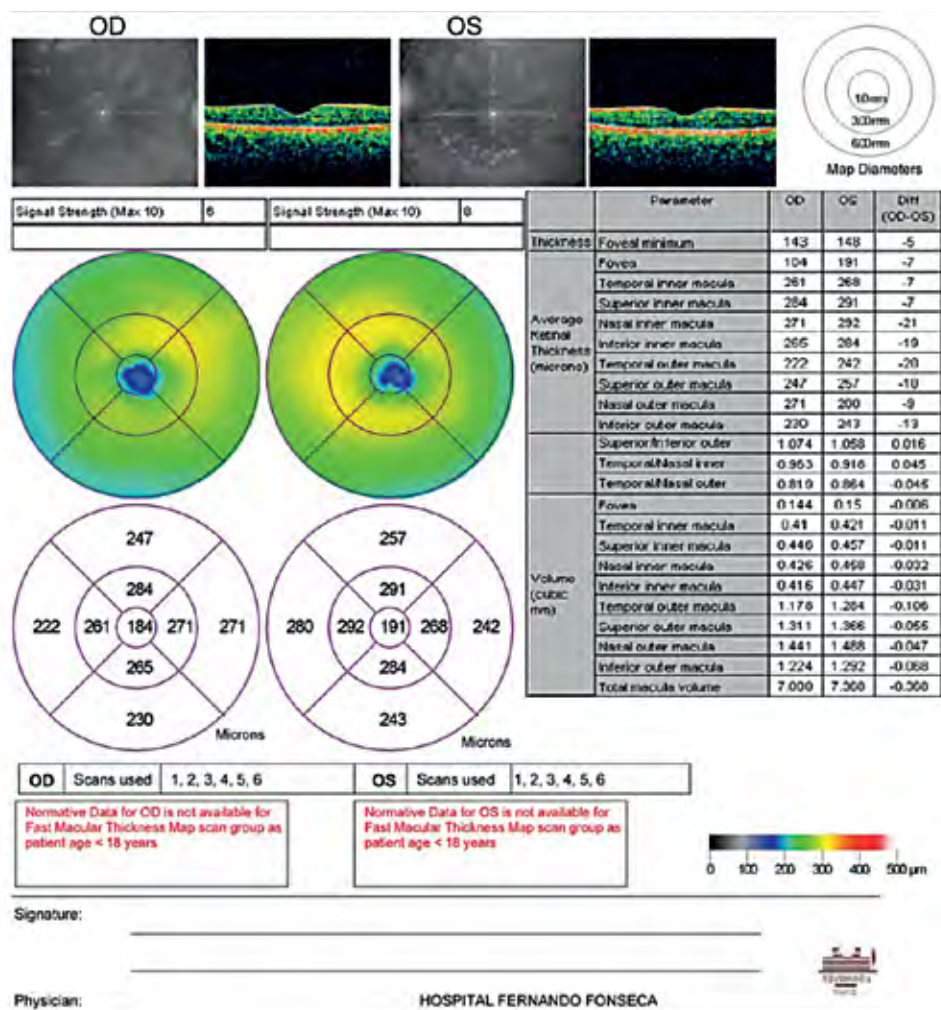


Fig. 1 | Sample OCT images from a patient with unilateral amblyopia due to strabismus.

inner nasal, inner inferior and outer inferior macular areas of the amblyopic eye (table 1).

Macular volume and retinal thickness in the other macular areas were reduced in amblyopic eyes but this was not statistically significant.

DISCUSSION

Functional and clinical changes are known to occur in patients with amblyopia, including reduced visual acuity and contrast sensitivity, disturbance of colour vision and motion sense or pupillary abnormalities³.

The deleterious effects of amblyopia in visual structures have long been studied but the results are conflicting.

Visual cortex changes were reported in experimental visual deprivation amblyopia, namely in layer IVe in V1⁶⁻⁹, the primary visual cortex; this does not seem to be the case in human strabismic and/or anisometropic amblyopes¹⁰⁻¹². Extrastriate abnormalities in some amblyopic patients have also been demonstrated by functional MRI and psychophysiological studies¹².

Lateral geniculate nucleus alterations have been well established in animals¹³ and in humans, with shrunken

cells in layers supplied by the amblyopic eye¹³⁻¹⁵. These changes are thought to be caused by retrograde inhibition originating in the visual cortex¹⁶.

As for retinal involvement, this is still a controversial issue. Recent technology has given us the opportunity of studying the retina *in vivo* and this has led to a wide number of studies in amblyopic patients, either using OCT, scanning laser polarimetry¹⁷ or confocal scanning laser ophthalmoscopy¹⁸ in order to assess retinal changes. Several works using OCT have focused on the macula¹⁹⁻²¹, the optic nerve²²⁻²⁵ or both²⁶⁻³³, with contradictory results.

Park *et al*²¹ studied macular thickness in 20 amblyopic patients using spectral domain OCT (SD-OCT); amblyopia was caused by strabismus, anisoastigmatism and unilateral ptosis. In their study, they found significant thinning of several retinal layers in amblyopic eyes, especially in the ganglion cell layer+inner plexiform layer, and suggested those changes could be caused by retrograde inhibition originating in the striate cortex. It was also found that some of the studied layers were thicker in some macular locations and thinner in others, raising the possibility that different macular areas undergo different pathological changes in amblyopia.

31 children with amblyopia due to unilateral high myopia were studied by Pang *et al*²⁰ using Stratus OCT3 and were found to have significant higher minimum foveal thickness and average foveal thickness but lower inner and outer macular thickness in amblyopic eyes. Similar results were found in a large population-based study, The Sydney Childhood Eye Study, by Huynh *et al*³¹. OCT scan data was studied in 3529 patients with strabismic or anisometropic amblyopia, showing significant greater foveal minimum thickness in amblyopic than in non-amblyopic eyes, as well as greater central macular thickness in amblyopic eyes, although the later was not significant. The inner macular ring was also significantly thinner in amblyopic children, with no difference found in outer macular ring thickness.

Several other studies have been performed in amblyopic patients. Yoon *et al*²⁶ found no significant difference in macular thickness in 31 patients with unilateral hyperopic amblyopia. The same was found by Altintas *et al*²⁷, who investigated 14 unilateral strabismic amblyopic patients and concluded there was no difference between macular thickness and volume between both eyes. Kee *et al*²⁸ compared 26 strabismic and/or anisometropic amblyopic patients with 42 normal children and also found no significant difference in foveal thickness between both groups. On the other hand, Dickmann *et al*²⁹ concluded that foveal volume and macular thickness was higher in

Table 1 | Results.

Thickness (µm)			
Foveal minimum	185.16	177.63	7.53*
Average foveal (1 mm)	204.95	206.32	-1.37
Inner macula (3 mm)			
Nasal	279.79	285.63	-5.84*
Superior	281.90	285.84	-3.94
Temporal	267.58	269.53	-1.95
Inferior	279.11	285.00	-5.89*
Outer macula (6 mm)			
Nasal	277.05	273.05	4.00
Superior	257.21	257.32	-0.11
Temporal	236.26	240.05	-3.79
Inferior	245.68	252.79	-7.11*
Volume (mm ³)	7.27	7.37	-0.1

Macular thickness in different areas and macular volume. The marked differences (*) were statistically significant (α=0.05) in the Wilcoxon signed rank test.

strabismic amblyopia but not in anisometropic amblyopia. Al-Haddad *et al*³³, studying 82 unilateral amblyopic patients with SD OCT, identified an increased central macular thickness in the amblyopic eyes but this was only significant in the anisometropic patients and not in the strabismic group. Finally, Aguirre *et al*²⁹ compared 68 normal and 124 uni or bilateral ametropic amblyopic eyes, having found the retinas of amblyopic eyes to have a more considerable macular thickness than normal eyes, at least in some areas.

The conflicting results of all the above mentioned studies reflect the different experimental settings used, especially regarding the type of amblyopia (strabismic, anisometropic or both; unilateral vs bilateral amblyopia), the mean age of the studied populations and the detection technology used (TD vs SD OCT).

Some animal studies have demonstrated abnormal findings in retinal structures, namely degeneration of retinal ganglion cells^{34,35}, thinning of the IPL and decreased nucleolar volume of RGC³⁶ and a decrease in the density of Müller fibers³⁷. We speculate that this could have happened in our population. Also, as Park *et al*²¹, we hypothesize these changes may have been caused by retrograde inhibition originating in the striate cortex.

Our study has several limitations. The small number of patients makes it difficult to generalize our results. Also, the number of anisometropic amblyopic patients should have been higher, in order to assess any possible differences between strabismic and anisometropic amblyopia. Higher resolution technology, such as SD OCT, could have helped us establishing which specific layers were responsible for the macular thickness differences found in our patients.

In conclusion, there seems to be a difference in macular thickness between both eyes in patients with unilateral amblyopia due to strabismus or anisometropia, at least in some areas. More large studies, such as the Sydney Childhood Eye Study³¹, are required to confirm retinal changes in amblyopia.

REFERENCES

- Eibschitz-Tsimhoni M, Friedman T, Naor J, et al. Early screening for amblyogenic risk factors lowers the prevalence and severity of amblyopia. *J AAPOS* 2000; 4: 194-9.
- Simons K. Amblyopia characterization, treatment, and prophylaxis. *Surv Ophthalmol* 2005; 50: 123-66.
- Tong LM. Unifying concepts in mechanism of amblyopia. *Med Hypotheses* 1997; 48: 97-102.
- Siegel, S. Nonparametric statistics for the behavioral sciences. New York: McGraw-Hill Book Co. 1956. p. 75-83.
- Wilcoxon, F. Individual Comparisons by ranking methods. *Biometrics* 1945; 1: 80-83.
- Hubel DH, Wiesel TN. The period of susceptibility to the physiological effects of unilateral eye closure in kittens. *J Physiol* 1970; 206: 419-36.
- Daw NW, Wyatt HJ. Kittens reared in a unidirectional environment: evidence for a critical period. *J Physiol* 1976; 257: 155-70.
- Daw NW, Berna NE, Ariel M. Interaction of critical periods in the visual cortex of kittens. *Science* 1978; 199: 565-7.
- Harwerth RS, Smith EL, Dunca GC et al. Multiple sensitive periods in the development of the primate visual system. *Science* 1986; 232: 235-8.
- Horton JC, Hocking DR. Pattern of ocular dominance columns in human striate cortex in strabismic amblyopia. *Vis Neurosci* 1996; 13: 787-95
- Horton JC, Stryker MP. Amblyopia induced by anisometropia without shrinkage of ocular dominance columns in human striate cortex. *Proc Natl Acad Sci USA* 1993; 90: 5494- 8.
- Hoyt CS. Amblyopia: a neuro-ophthalmic view. *J Neuroophthalmol.* 2005; 25: 227-31.
- Wiesel TN, Hubel DH. Effects of visual deprivation on morphology and physiology of cells in the cats lateral geniculate body. *J Neurophysiol* 1963; 26: 978-93.
- von Noorden GK, Crawford ML. The lateral geniculate nucleus in human strabismic amblyopia. *Invest Ophthalmol Vis Sci* 1992; 33: 2729-32.
- von Noorden GK, Crawford ML, Levacy RA. The lateral geniculate nucleus in human anisometropic amblyopia. *Invest Ophthalmol Vis Sci* 1983; 24: 788-90.
- Demer JL, von Noorden GK, Volkow ND, Gould KL. Brain activity in amblyopia. *American Orthoptic Journal* 1991; 41: 56-57.
- Baddini-Caramelli C, Hatanaka M, Polati M, Umino AT, Susanna R Jr. Thickness of the retinal nerve fiber layer in amblyopic and normal eyes: a scanning laser polarimetry study. *J AAPOS* 2001; 5: 82-4.
- Miki A, Shirakashi M, Yaoeda K, Kabasawa Y, Ueki S, Takagi M et al. Optic disc measurements using the Heidelberg Retina Tomograph in amblyopia. *Clin Ophthalmol* 2010; 4: 1025-8.
- Aguirre F, Mengual E, Hueso JR, Moya M. Comparison of normal and amblyopic retinas by optical coherence

- tomography in children. *Eur J Ophthalmol* 2010; 20: 410-8.
20. Pang Y, Goodfellow GW, Allison C, Block S, Frantz KA. A prospective study of macular thickness in amblyopic children with unilateral high myopia. *Invest Ophthalmol Vis Sci* 2011; 52: 2444-9.
21. Park KA, Park do Y, Oh SY. Analysis of spectral-domain optical coherence tomography measurements in amblyopia: a pilot study. *Br J Ophthalmol* 2011; 95: 1700-6.
22. Yen MY, Cheng CY, Wang AG. Retinal nerve fiber layer thickness in unilateral amblyopia. *Invest Ophthalmol Vis Sci* 2004; 45: 2224-30.
23. Repka MX, Goldenberg-Cohen N, Edwards AR. Retinal nerve fiber layer thickness in amblyopic eyes. *Am J Ophthalmol* 2006; 142: 247-51.
24. Repka MX, Kraker RT, Tamkins SM, Suh DW, Sala NA et al; Pediatric Eye Disease Investigator Group. Retinal nerve fiber layer thickness in amblyopic eyes. *Am J Ophthalmol* 2009; 148: 143-7.
25. Miki A, Shirakashi M, Yaoeda K, Kabasawa Y, Ueki S, Takagi M et al. Retinal nerve fiber layer thickness in recovered and persistent amblyopia. *Clin Ophthalmol* 2010; 4: 1061-4.
26. Yoon SW, Park WH, Baek SH, Kong SM. Thicknesses of macular retinal layer and peripapillary retinal nerve fiber layer in patients with hyperopic anisometropic amblyopia. *Korean J Ophthalmol* 2005; 19: 62-7.
27. Altintas O, Yüksel N, Ozkan B, Caglar Y. Thickness of the retinal nerve fiber layer, macular thickness, and macular volume in patients with strabismic amblyopia. *J Pediatr Ophthalmol Strabismus* 2005; 42: 216-21.
28. Kee SY, Lee SY, Lee YC. Thicknesses of the fovea and retinal nerve fiber layer in amblyopic and normal eyes in children. *Korean J Ophthalmol* 2006; 20: 177-81.
29. Dickmann A, Petroni S, Salerni A, Dell'Omo R, Bales-trazzi E. Unilateral amblyopia: An optical coherence tomography study. *J AAPOS* 2009; 13: 148-50.
30. Quoc EB, Delepine B, Tran TH. Thickness of retinal nerve fiber layer and macular volume in children and adults with strabismic and anisometropic amblyopia. *J Fr Ophthalmol* 2009; 32: 488-95.
31. Huynh SC, Samarawickrama C, Wang XY, Rochtchina E, Wong TY, Gole GA et al. Macular and nerve fiber layer thickness in amblyopia: the Sydney Childhood Eye Study. *Ophthalmology* 2009; 116: 1604-9.
32. Dickmann A, Petroni S, Perrotta V, Salerni A, Parrilla R, Aliberti S et al. A morpho-functional study of amblyopic eyes with the use of optical coherence tomography and microperimetry. *J AAPOS* 2011; 15: 338-41.
33. Al-Haddad CE, Mollayess GM, Cherfan CG, Jaafar DF, Bashshur ZF. Retinal nerve fibre layer and macular thickness in amblyopia as measured by spectral-domain optical coherence tomography. *Br J Ophthalmol* 2011; 95: 1696-9.
34. von Noorden GK, Crawford ML, Middleditch PR. Effect of lid suture on retinal ganglion cells in *Macaca mulatta*. *Brain Res* 1977; 122: 437-44.
35. Chow KL, Riesen AH, Newell FW. Degeneration of retinal ganglion cells in infant chimpanzees reared in darkness. *J Comp Neurol* 1957; 107: 27-42.
36. Rasch E, Swift H, Riesen AH, Chow. Altered structure and composition of retinal cells in darkreared mammals. *Exp Cell Res* 1961; 25: 348-63.
37. Weiskrantz L. Sensory deprivation and the cat's optic nervous system. *Nature* 1958; 181: 1047-50.

Este trabalho foi apresentado como comunicação oral no XVIII Congresso Latinoamericano de Estrabismo, México, Novembro de 2010 e no 53º Congresso Português de Oftalmologia, Vilamoura, Dezembro de 2010

Os autores não têm conflitos de interesse a declarar

CONTACTO

Filipe Silva
Serviço de Oftalmologia
Hospital Prof. Dr. Fernando Fonseca EPE
Venteira, IC 19, 2720-276, Amadora, Portugal
ssfilipe@gmail.com