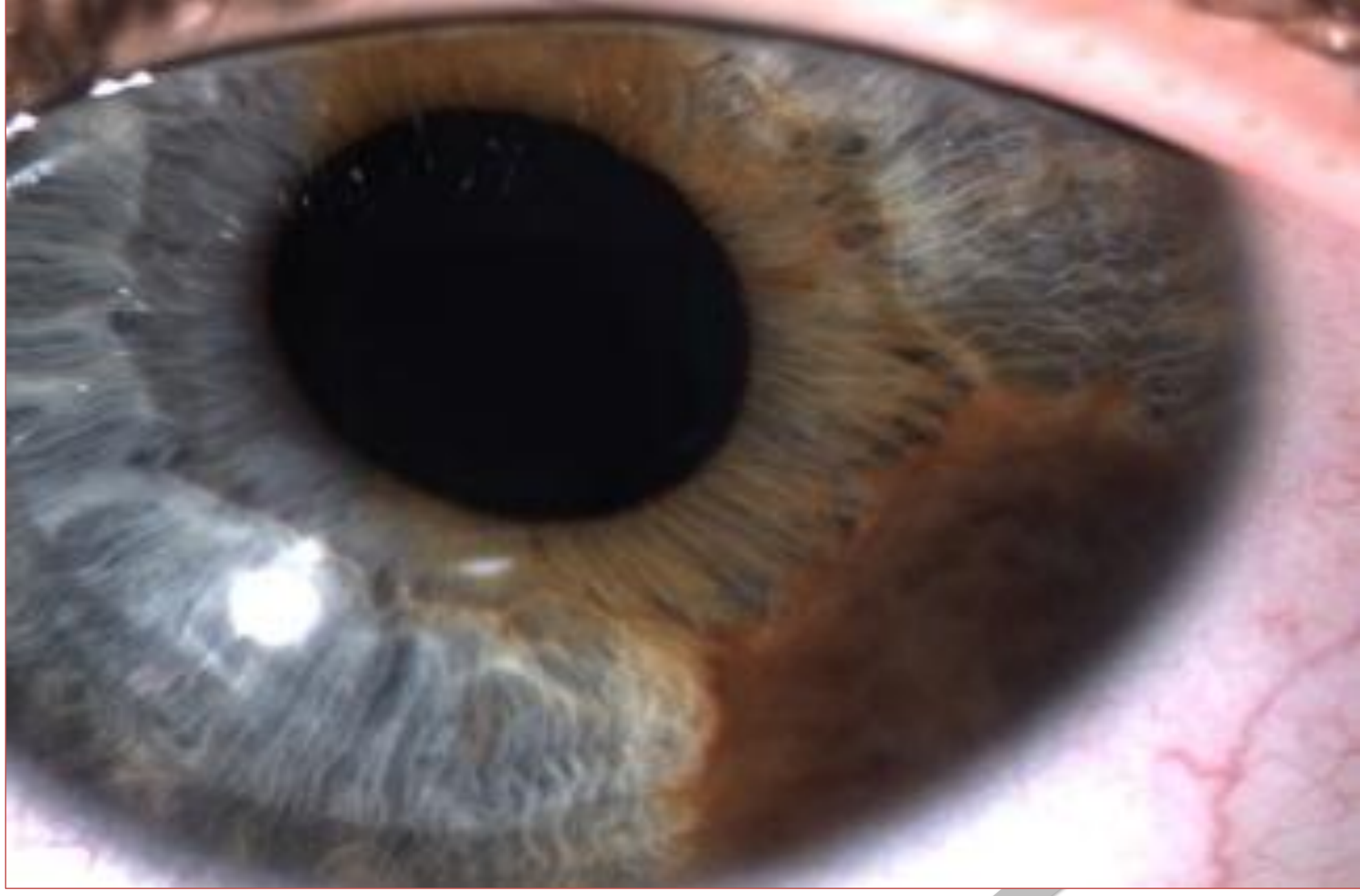


Cataract After Proton Beam Therapy (PBT) for Iris Melanoma

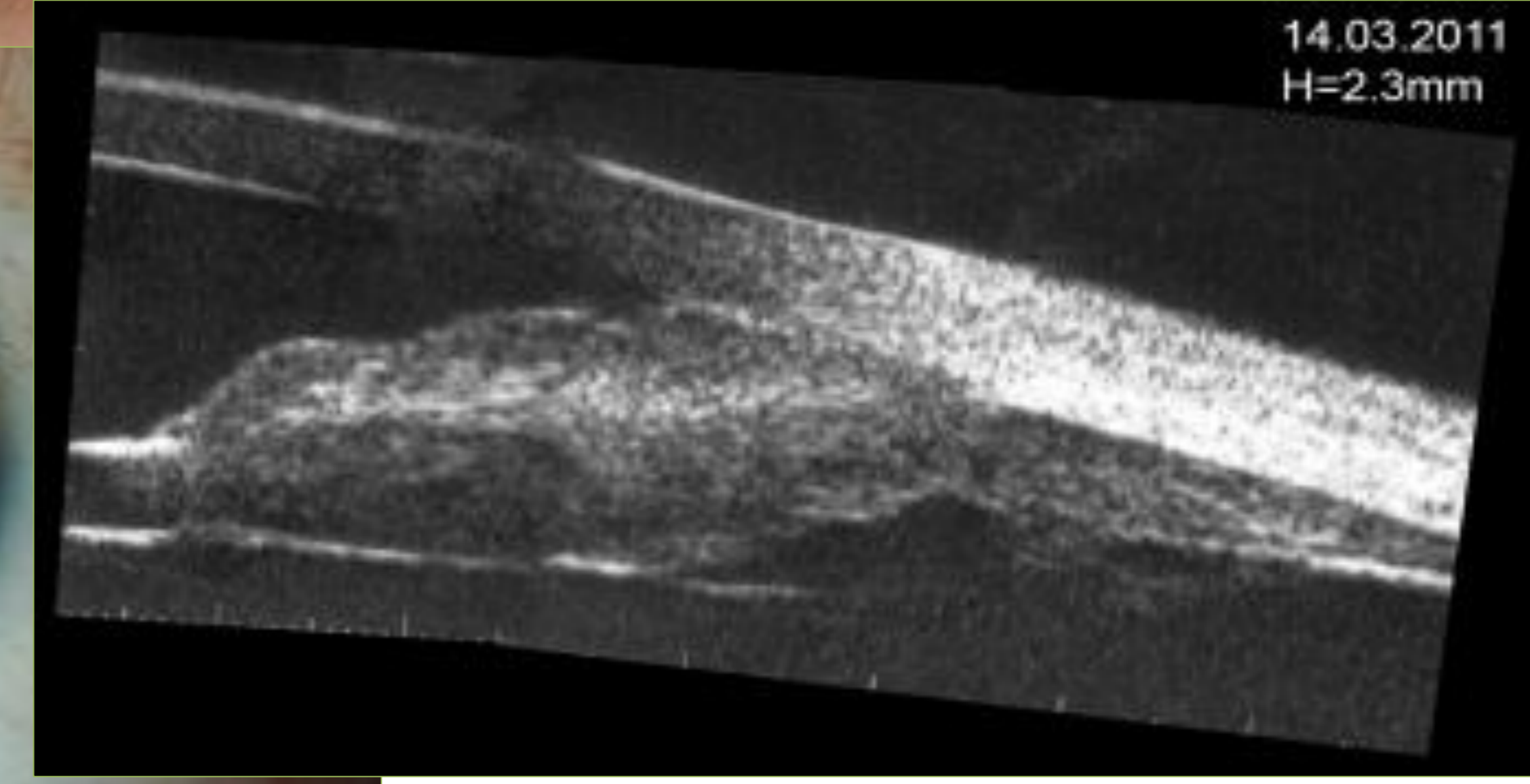
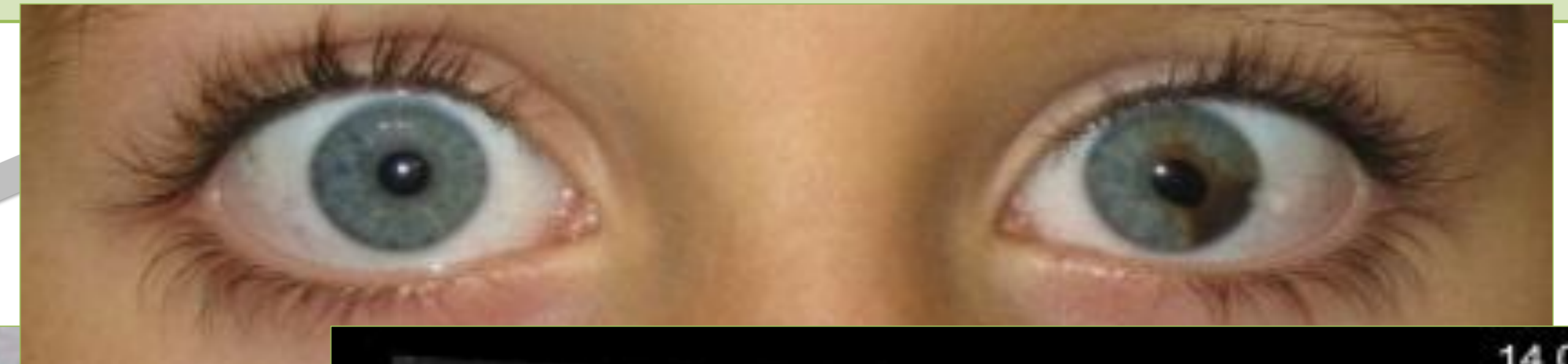
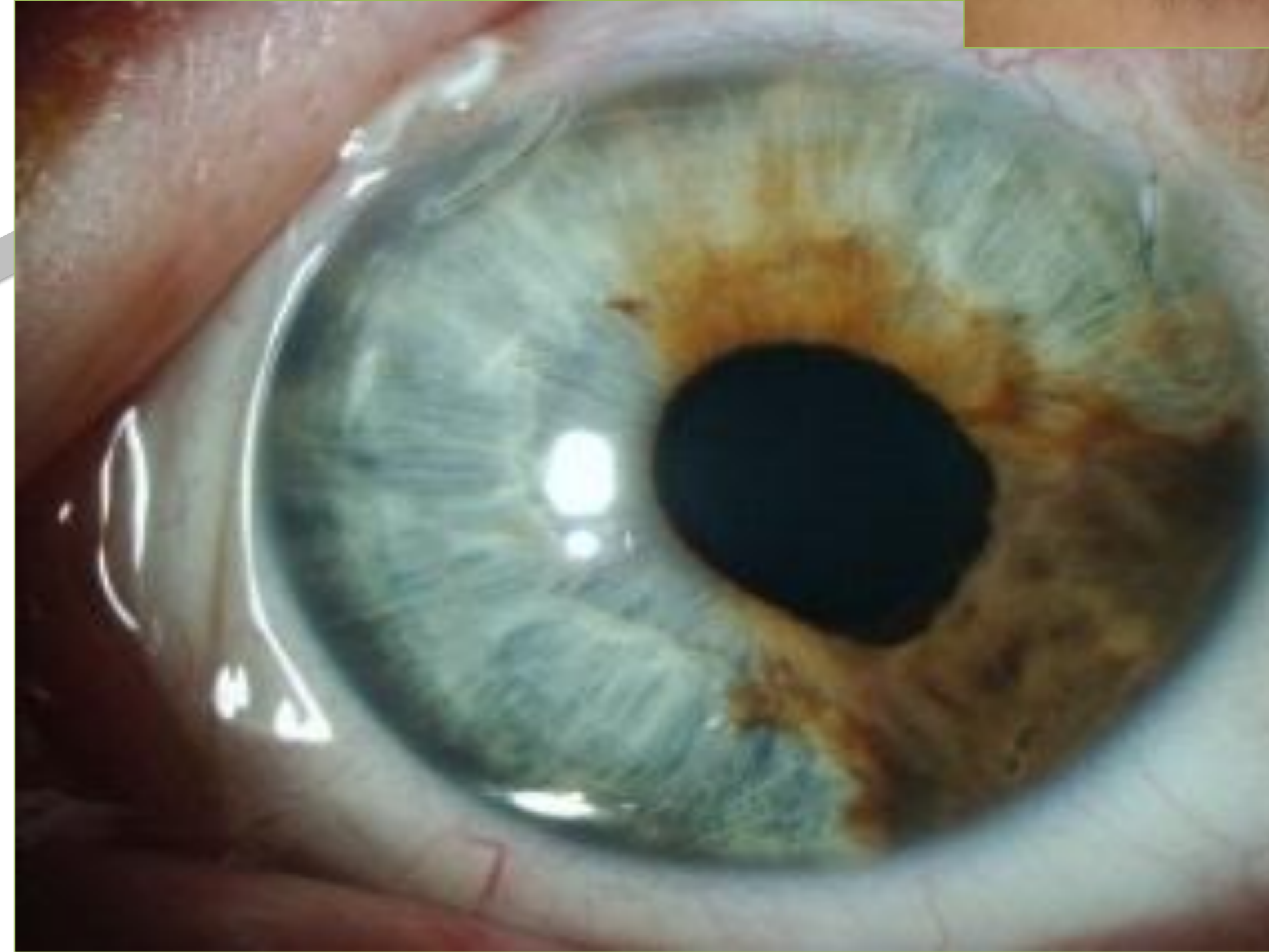
Inês Coutinho, Peter Pêgo, Mário Ramalho, Catarina Pedrosa, Isabel Prieto, João Cabral

1 ♂, 8 years
Pigmented lesion in the inferotemporal iris of the left eye
Iris Nevus

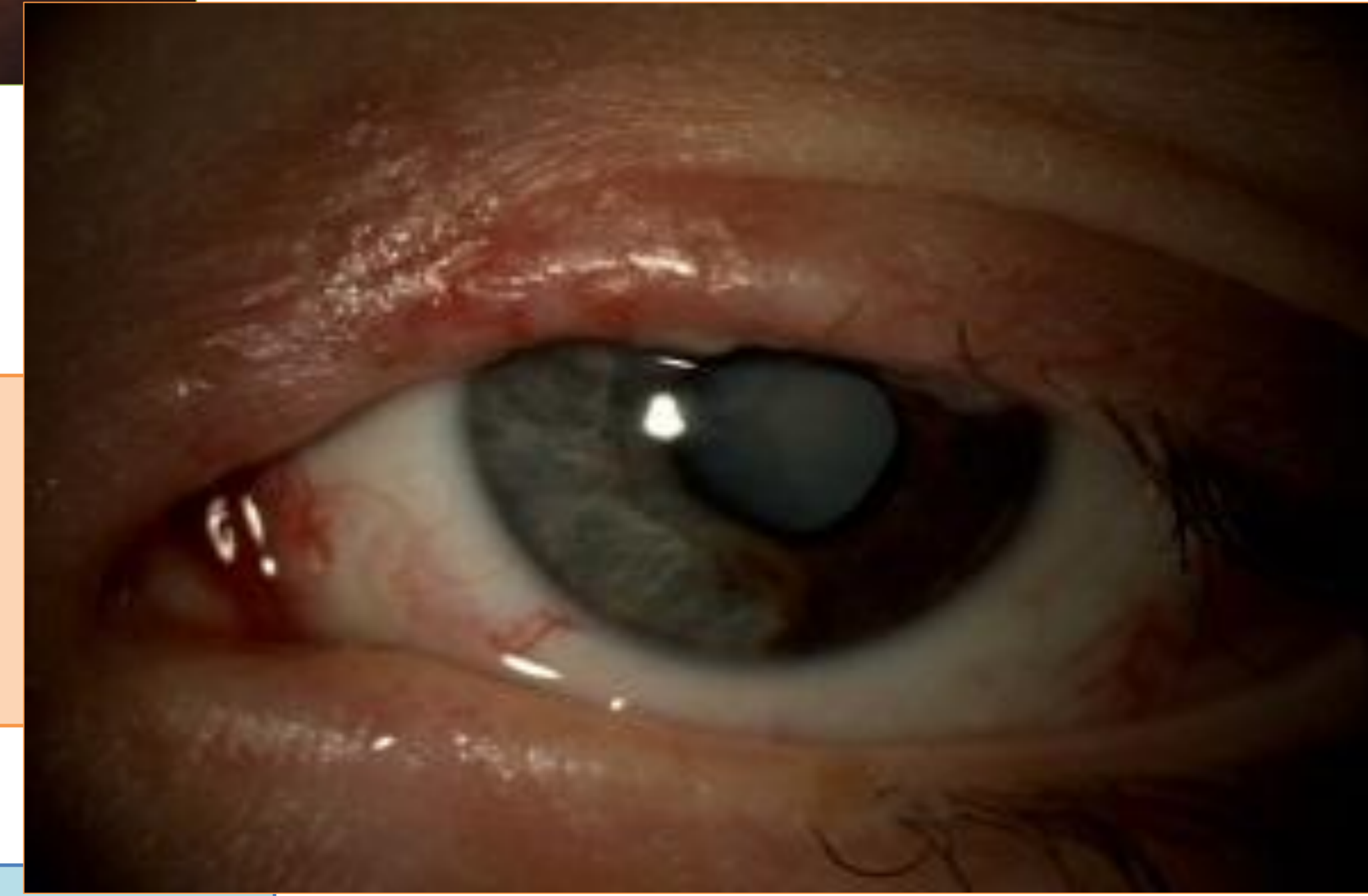


2 6 months later, the lesion grown in diameter and thickness associated with corectopia and ectropion uveae but did not involve the angle or ciliary body
Diffuse Iris Melanoma

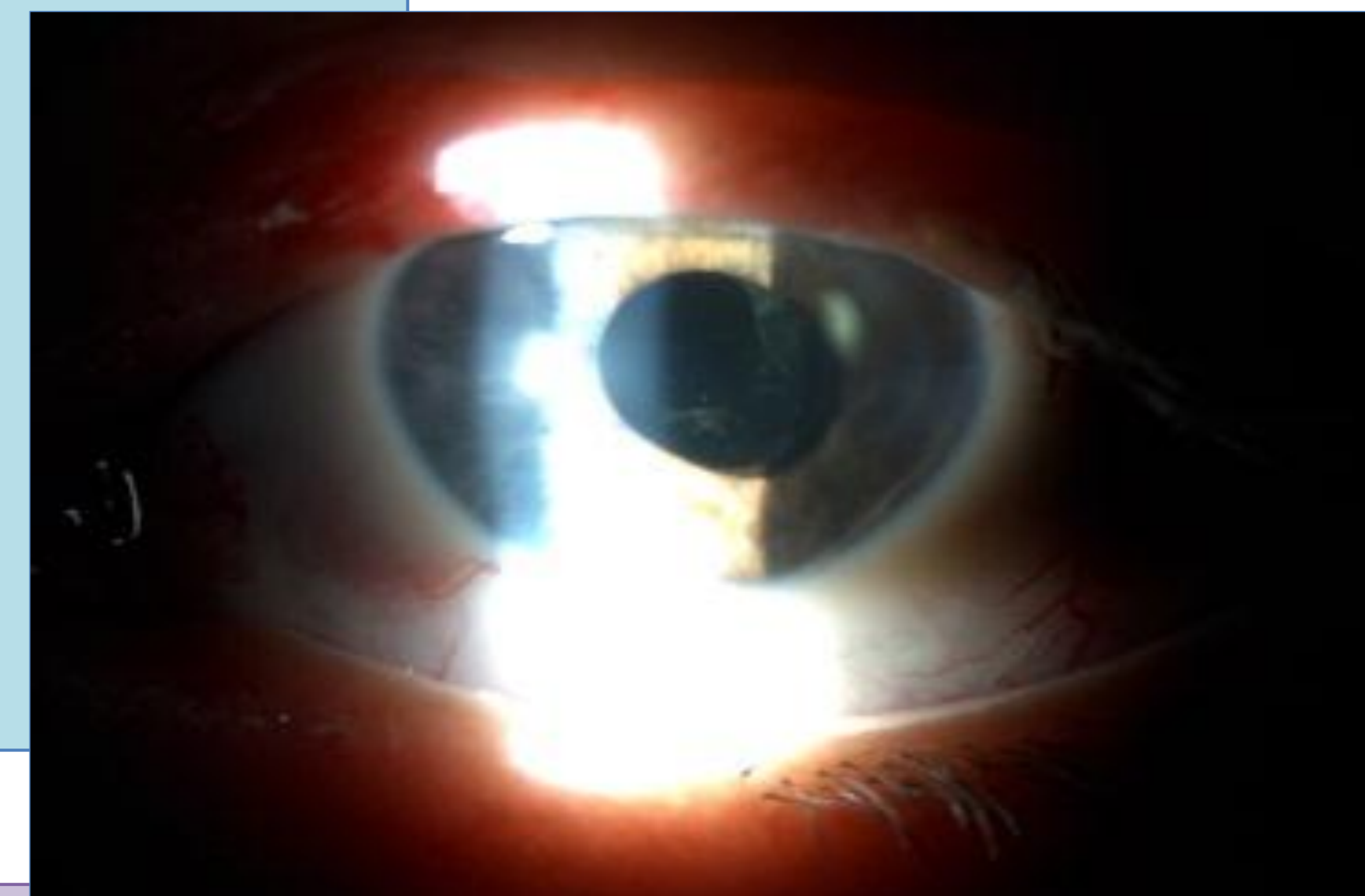


3 It was performed PBT

4 18-months, after PBT, the patient developed a posterior subcapsular cataract in OS



5 At age of 11, it was performed a micro-incision phacoemulsification cataract surgery combined with primary posterior capsulorexis, intracameral triamcinolone injection and implantation of a simple piece intraocular lens. No intra-operative complications were observed



6 After 9 months of follow up, the BCVA is 20/20 in OS, without complications

Conclusion

Primary PBT was well tolerated and 3 years after we didn't report any recurrence of the tumour neither evidence of metastatic disease. The main complication was cataract, since in the eye, the lens is the most radiosensitive tissue.

Cataracts due to radiation are more linked to be posterior capsular opacities and it is advisable to wait 2 years after PBT prior to performing cataract surgery, in order to observe a good regression of the tumour.

Surgeons should be aware that capsule is sometimes difficult to clean and that inflammatory reactions after surgery can be severer than for a standard surgery.

Paediatric cataract surgery is also a complex procedure with all aspects of the surgical process requiring care and attention. The use of micro-incision phacoemulsification with intracameral triamcinolone and posterior capsulorexis seems to provide significantly less anterior segment inflammation and no visual axis obscuration after cataract surgery with IOL implantation.

Bibliography:

Jager MJ, Desjardins L, Kivela T, Damato BE (eds): Current Concepts in Uveal Melanoma. Dev Ophthalmol. Basel, Karger, 2012, vol 49, pp 16-26; 41-57