

Case 12394

Unilateral phrenic nerve neuropathy as an early sign of recurrent mediastinal Hodgkin's disease

Elsa Rosado¹, Emmanouil Amanakis², Daniela Sperl³,
Erich Sorantin²

Section: Paediatric Radiology

Published: 2014, Dec. 23

Patient: 14 year(s), male

Authors' Institution

¹ Department of Radiology, Hospital Prof. Doutor Fernando Fonseca; IC-19 2720-276 Amadora, Portugal

² Division of Pediatric Radiology, Department of Radiology, Medical University Graz; Auenbruggerplatz 34, A - 8036 Graz, Austria

³ Division of Pediatric Hemato/Onkology, Department of Pediatric and Adolescent Medicine, Medical University Graz; Auenbruggerplatz 34, A - 8036 Graz, Austria

Clinical History

A 14 year old boy with previous mediastinal Hodgkin lymphoma, treated with chemotherapy, in complete remission for 4 months, presented with dyspnea, which was worse in the lying position and when he was playing the trumpet. A few months later recurrent Hodgkin Lymphoma was diagnosed by mediastinal lymphadenopathy.

Imaging Findings

Chest radiogram and mediastinal ultrasonography revealed no detectable lesions in the mediastinum. In addition both diaphragms were in normal position. A subsequent functional MRI of the diaphragms showed impaired movement on the left, thus establishing the diagnosis of phrenic nerve neuropathy (Fig.1a, b). All other findings were normal and there was no lymphadenopathy.

Dynamic evaluation of diaphragm motility was achieved with an ultrafast SSFP sequence. During deep breathing several respiratory cycles were acquired in coronal and axial orientation. The lung area on coronal slices was segmented semi-automatically in both hemithorax. The area change during the respiratory cycle is caused by the activity of respiratory muscles, with main contribution from the diaphragm. Therefore the change in area can be regarded as a surrogate parameter of diaphragmatic function (Fig.2a). Afterwards areas of both hemithorax were plotted for every timepoint on one chart (Fig.2b). This represents a novel method for assessment diaphragmatic function.

Discussion

Hodgkin's Disease accounts for 1/6th of all cancers in adolescents and young adults [1, 2]. The disease is likely to present as asymptomatic cervical or axillary lymphadenopathy, but sometimes the initial presentation includes systemic symptoms such as fever, weight loss, drenching night sweats or fatigue [2].

In mediastinal Hodgkin lymphoma, diaphragmatic paralysis is a well-known complication, due to either tumor invasion or a complication of radiation therapy [3]. Neurotoxicity is also a possible adverse effect of several chemotherapeutic drugs. However, in most cases it is dose related and manifests during the course of treatment [4, 5]. To the best of our knowledge, neuropathy as a late complication of chemotherapy was never reported.

In our case, at the onset of the symptoms, the patient was already in remission for a period of four months, confirmed by imaging and laboratory controls performed frequently. It is unlikely that in this case phrenic nerve neuropathy was related to previous therapy as he had never received irradiation and he had completed the chemotherapeutic cycle more than six months earlier, with no reported side effects related to the drug administration.

Traditionally, diaphragmatic movement has been evaluated by fluoroscopy. M-mode ultrasonography can also be used to assess diaphragmatic movement quantitatively, and it has been shown to be superior to fluoroscopy, especially in children [6]. More recently, cine balanced steady-state free precession sequences employing steady-state acquisition have been used for quantitative evaluation of excursion, synchronicity and velocity of diaphragmatic motion [6]. Functional MRI enables classifying diaphragmatic dysfunction and discrimination of phrenic palsy and diaphragmatic relaxation. The presented method allows to chart the dysfunction and in addition performance metrics could be calculated. In this case phrenic neuropathy was the first and only sign of recurrent Hodgkin Lymphoma.

Final Diagnosis

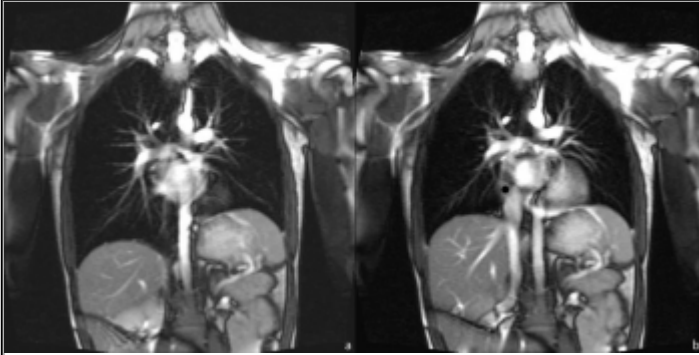
Phrenic nerve neuropathy due to recurrent mediastinal Hodgkin lymphoma.

Differential Diagnosis List

Phrenic nerve neuropathy due to tumor invasion, Phrenic nerve neuropathy due to radiation therapy, Phrenic nerve neuropathy due to neurotoxicity of chemotherapy drugs, Phrenic nerve neuropathy related to complications of central venous catheter placement, Phrenic nerve neuropathy caused by viral disease, Phrenic nerve neuropathy related to pulmonary infection / inflammation

Figures

Figure 1 MRI

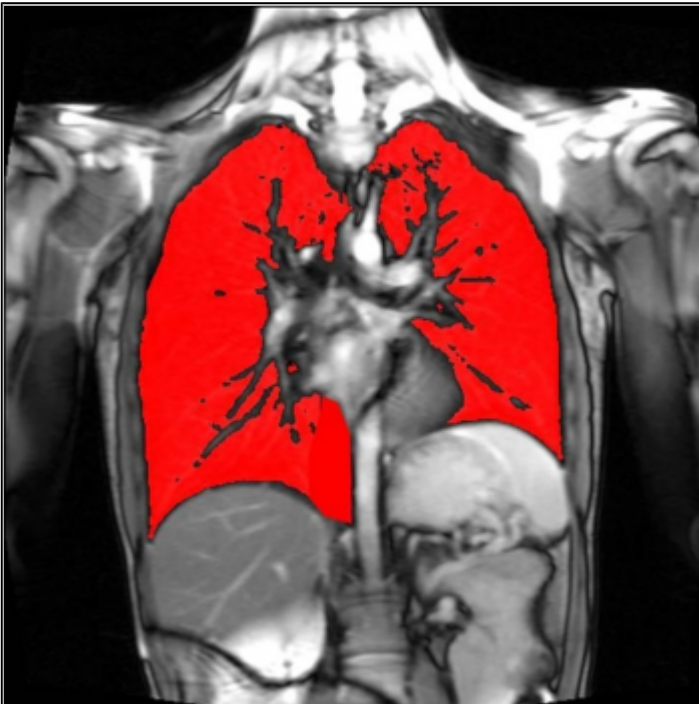

Coronal True FISP MR images of the thorax (TR: 337ms, TE: 1,33ms) in maximum inspiration (a) and maximum expiration (b). The difference in the position of both hemidiaphragms is clearly depicted.

© Sorrantin E, Div. of Pediatric Radiology, Department of Radiology, Medical University Graz, Austria

Area of Interest: Thorax;
Imaging Technique: MR;
Procedure: Diagnostic procedure;
Special Focus: Lymphoma;

Figure 2 Functional MRI



Coronal True FISP MR image of the thorax (TR: 337ms, TE: 1,33ms) in maximum inspiration showing the segmented lung areas (red color) of both hemithorax.

© Sorrantin E, Div. of Pediatric Radiology, Department of Radiology, Medical University Graz, Austria

Area of Interest: Thorax;
Imaging Technique: MR-Functional imaging;
Procedure: Diagnostic procedure;

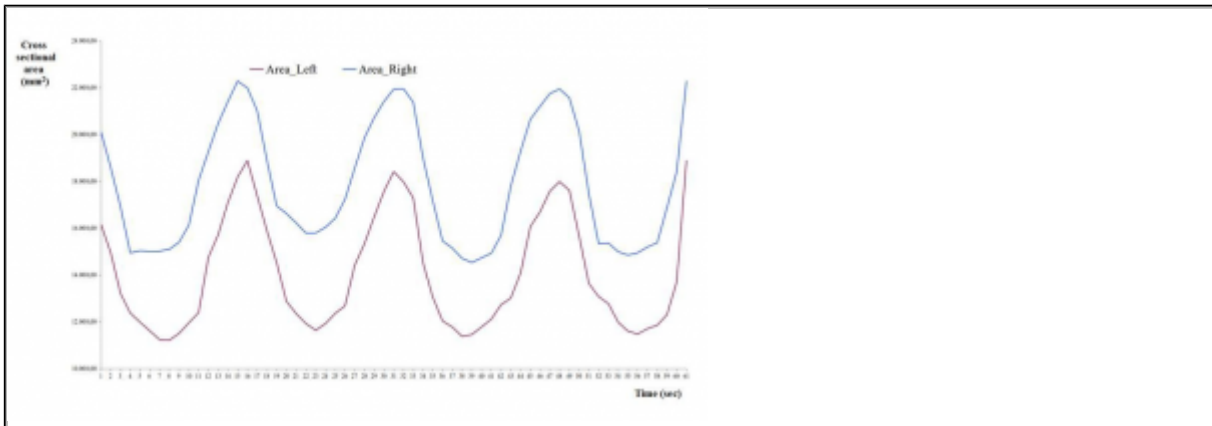


Diagram of the motility of the two hemidiaphragms. The area change during the respiratory cycle corresponds to diaphragmatic function. Blue line corresponds to healthy right side, red one to diseased left side.

© Sorrantin E, Div. of Pediatric Radiology, Department of Radiology, Medical University Graz, Austria

Area of Interest: Thorax;
Imaging Technique: MR-Functional imaging;
Procedure: Diagnostic procedure;
Special Focus: Lymphoma;

References

- [1] Swerdlow AJ. (2003) Epidemiology of Hodgkin's disease and non-Hodgkin's lymphoma. *Eur J Nucl Med Mol Imaging* 30(1): S3-S12
- [2] Toma P, Granata C, Rossi A, Garaventa A (2007) Multimodality Imaging of Hodgkin Disease and Non-Hodgkin Lymphomas in Children. *RadioGraphics* 27:1335-1354
- [3] Brander PE, Järvinen V, Lohela P, Salmi T. (1997) Bilateral diaphragmatic weakness: a late complication of radiotherapy. *Thorax* 52:829-831
- [4] Gomber S, Dewan P and Chhonker D. (2010) Vincristine Induced Neurotoxicity in Cancer Patients. *Indian J Pediatr* 77:97-100
- [5] Dunlap B, Paice JA. (2006) Chemotherapy-Induced Peripheral Neuropathy: A Need for Standardization in Measurement. *J Support Oncol* 4:398-399
- [6] Chavhan GB, Babyn PS, Cohen RA, Langer JC. (2010) Multimodality Imaging of the Pediatric Diaphragm: Anatomy and Pathologic Conditions. *RadioGraphics* 30:1797-1817

Citation

Elsa Rosado¹, Emmanouil Amanakis², Daniela Sperl³,
Erich Sorantin² (2014, Dec. 23)

Unilateral phrenic nerve neuropathy as an early sign of recurrent mediastinal Hodgkin's disease {Online}

URL: <http://www.eurorad.org/case.php?id=12394>